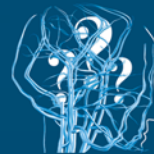


The Hungarian Journal of

# VASCULAR DISEASES

2019/3



**Another Phlebology '19**

Conference  
on Practical Questions

**Scientific Program  
and Abstract book**

4-5 October 2019  
Hotel Mercure Castle Hill,  
Budapest, Hungary



*Dr. Bartos Gábor és mtsai.  
Soltész emlékérmesek*




The Hungarian Society for Angiology and Vascular Surgery  
The Hungarian Society for Cardiovascular and Interventional Radiology



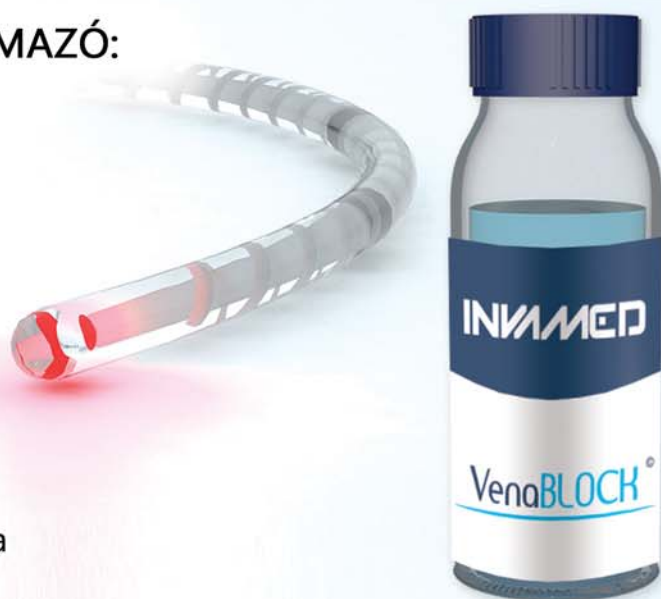# INVA MED

RD  
GLOBAL  
Research & Development

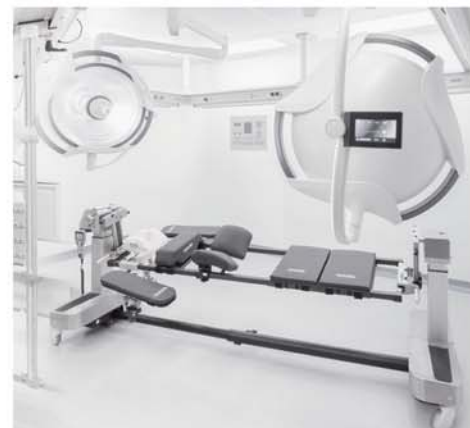

KIZÁRÓLAGOS MAGYARORSZÁGI FORGALMAZÓ:  
Medropolitan Consulting Kft.

SZINERGIÁK A MŰTŐBEN  
**MEDROPOLITAN**  
SYNERGIES IN THE OR



- **FORRADALMI**, sokoldalúan használható **AUTOLÓG FIBRINRAGASZTÓ** technológia
- Kiemelkedő minőségű és kiváló ár-érték arányú **KÉZI MŰSZEREK** és **MŰTÉTI ENDOSZKÓPOS RENDSZEREK** teljes választéka
- Speciális és általános **MŰTŐASZTALOK, MŰTŐLÁMPÁK**



További információkért lépjenek velünk kapcsolatba az alábbi elérhetőségeken:  
[www.medropolitan.hu](http://www.medropolitan.hu)  
[medropolitan@medropolitan.hu](mailto:medropolitan@medropolitan.hu)

+36 20 429 0845  
+36 20 236 0708



## Welcome Message



On behalf of the Hungarian Venous Forum and the Hungarian Society of Angiology and Vascular Surgery, it is a great pleasure to invite you to join us at our international meeting, the Another Phlebology Symposium.

This is the 3rd occasion that we are organising this stimulating meeting, getting together to discuss some fresh and useful ideas within phlebology.

The previous ones in 2014 and 2017 were very successful, and inspired us to turn this into a series of meetings in Budapest. Our aim is a little different from that of other conferences. We prefer to speak about very innovative and unknown things, rather than prove topics which have already been proved many times before. This means we would like to discuss both recent observations, works in progress without strong supportive evidence, and other things not really new, but not yet mainstream in our discipline. At the same time, we intend to keep these presentations practical. There are other ideas used only by a few colleagues, which could be beneficial for many patients. We are also looking for some non-evidence-based dogmas, and trying to get rid of them.

We are very glad that our region, which previously lagged behind western countries in terms of phlebology, has become so active and creative in the last few decades. Most of the presentations are from this region.

A new thing at this conference is that the best presentation in general and in miniphlebectomy and glue surgery will get an award.

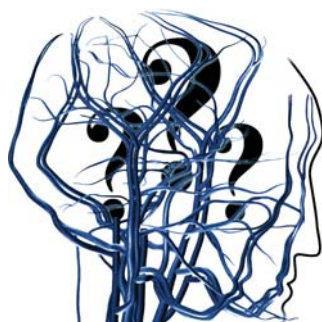
We invite you to Budapest, one of the most beautiful capitals in the world. There are a lot of museums, archaeological findings, special Hungarian restaurants, pubs, folk music, classical concerts, theatres, excursions and walking tour possibilities, thermal baths, stunning view from various points of the city.

We hope you enjoy your time here!

Dr. Imre Bihari  
*Chair of the Conference*



# Another Phlebology



**4-5 October 2019**

**Hotel Mercure Castle Hill, 41-43 Krisztina körút, Budapest, Hungary, 1013**

Chair of the Conference

Dr. Imre BIHARI PhD

Associate Professor

Organising and Scientific Committee:

Prof. Dr. Gábor MENYHEI PhD

Dr. György NÁDASY PhD

Prof. Dr. Zsolt PÉCSVÁRADY PhD

Dr. István ROZSOS PhD

Dr. Tamás SÁNDOR PhD

Dr. Attila SZABÓ PhD

Dr. Győző SZOLNOKY PhD

Dr. Frantisek Zernovicky PhD

Invited speakers:

Prof. Pier Luigi ANTIGNIANI (Italy)

Prof. Kürsat BOZKURT (Turkey)

Prof. Larissa M. CHERNUKHA (Ukraine)

Prof. Judit DARÓCZY (Hungary)

Prof. Alexander FLOR (Austria)

Dr. René MILLERET (France)

Dr. Alfred OBERMAYER (Austria)

Dr. Malay PATEL (India)

Dr. Fausto PASSARIELLO (Italy)

Dr. Attila PUSKÁS PhD (Romania)

Dr. Christian RAGG (Germany)

Dr. Lars RASMUSSEN (Denmark)

Prof. Thomas SMITZ-TRIXEN (Germany)

Prof. Zoltan VÁRADY (Germany)

**Gold Sponsor: Servier Hungaria Kft.**

**Silver Sponsor: Medropolitan Kft.**

Exhibitors:

APC Pharmlog, Biolitec, Bluemed, Invamed, IZINTA, Medicor, Medropolitan, Medtronic, Servier

Information: [www.phlebology.hu](http://www.phlebology.hu), [imre.bihari.dr@gmail.com](mailto:imre.bihari.dr@gmail.com)



## General Information

### Conference Venue

Hotel Mercure Castle Hill, Budapest, Krisztina krt. 41-43. 1013  
Tel: 00-36-1-488 8100  
[www.mercure.com/Budapest](http://www.mercure.com/Budapest)

### Dates:

4-5 October 2019  
4 October, Friday 8.30 – 19.00  
5 October, Saturday 8.30 – 18.00

### Registration Desk is open

4 October, Friday 8.00 – 18.00  
5 October, Saturday 8.00 – 18.00

On Site Registration is available.

### Opening Ceremony

Friday, 4 October, 10.00 – 11.00, Hotel Mercure Buda, Budapest.  
Price included in the participation fee.  
Coffee breaks and lunch written in the program are covered by the registration fee, served in the exhibition area

### Hands-on course

(Endovascular Varicose Vein Treatment, not included in the registration fee)  
Friday 4 October 8.30 – 10.00

### Congress Dinner

(Hungarian Evening): Friday 4 October, 19.30 – 22.30 (not included in the registration fee)  
Márványmenyasszony Restaurant

### Congress Language

The official language of the conference is English.

### Liability and Insurance

Neither the Organisers nor the Conference Secretariat will assume any responsibility whatsoever for damage or injury to persons or property during the Conference.  
Participants are recommended to arrange their personal travel and health insurance.

### Changes

The Organisers reserve the right to adjust or change the programme as necessary.



# Scientific programme of the 3rd Another Phlebology Meeting

Friday 4 October

8.30 – 10.00 **Practical course (Ultrasound, Laser, Microwave, Radiofrequency, Glue, Sclerotherapy)**  
registration is required (*Chair: F. Zernovicky*)

*Opening Ceremony (Chair: T. Sándor, I. Bihari)*

10.00 – 10.05 **What does ‘Another Phlebology’ mean?** *I Bihari (Hungary)*  
10.05 – 10.10 **Names from the history of Hungarian Phlebology** *T Sándor (Hungary)*  
10.10 – 10.15 **The European diploma of phlebology** *S Vasdekis (Greece)*  
10.15 – 10.20 **Training path for European phlebologists** *D. Radu (Romania)*  
10.20 – 10.30 **The Journal of the Hungarian Society is 25 years old** *E Kolossváry (Hungary)*

10.30 – 10.50 Welcome reception

*Endothermal methods for varicose veins I (Chair: A Obermayer, I Rozsos)*

10.50 – 11.00 **Treatment of varicose veins with microwave** *I Rozsos et al. (Hungary)*  
11.00 – 11.10 **Cryo fibrosis** *R Milleret (France)*  
11.10 – 11.20 **Endovenous welding in minimally invasive treatment of chronic venous diseases**  
*L Chernukha, VL Horbovets et al. (Ukraine)*  
11.20 – 11.30 **Extracorporeal high-intensity-focused-ultrasound (HIFU) treatment  
of varicose veins – first in human study** *A Obermayer (Austria)*  
11.30 – 11.40 **Ultrasound guided laser ablation** *P Dragic et al. (Serbia)*  
11.40 – 11.50 **Histological changes following closure FAST treatment** *K Brachmann et al. (Germany)*  
11.50 – 12.00 **The use of laser thermoablation for the treatment of incompetent  
perforator veins – late results** *W Wozniak et al. (Poland)*  
12.00 – 12.10 **1- Year results of endovenous Laser therapy with longer wavelength  
(1940nm) and lesser energy density (LEVEL2 Study)** *T Schmitz-Rixen et al (Germany)*  
12.10 – 12.20 **Score system for recurrency probability after laser surgery for varicose veins**  
*I Bihari (Hungary)*  
12.20 – 12.35 **Invited speaker: L. Rasmussen et al. (Denmark) Recurrence after endovenous treatment:  
treatment options**  
12.35 – 12.50 **Discussion**

12.50 – 13.35 Lunch break

*Crural ulcers (Chair: M Patel, Gy Szolnoky)*

13.35 – 13.50 **Invited speaker: F Passariello (Italy) Quantitative haemodynamics by venous ultrasound**  
13.50 – 14.00 **Endovenous ablation of feeding vein is a good choice for therapy in patients  
with venous leg ulcer** *TP Rucigaj (Slovenia)*  
14.00 – 14.10 **Shave-therapy with simultaneous autodermoplasty for patients  
with extensive trophic ulcers** *Y Sorokvasha et al. (Russia)*  
14.10 – 14.20 **Wound care practices for infected venous leg ulcers and prudent use  
of antibiotics** *R Varghese et al. (India)*  
14.20 – 14.30 **Role of Vitamin D3 in the management of pain in C5- 6 chronic venous disease (CVD):  
need to include as an integral part of the treatment protocol** *M Patel et al. (India)*  
14.30 – 14.40 **Double focal compression bandaging** *C Sanchez (Spain)*  
14.40 – 14.50 **Can we use compression therapy in patients with cardiac failure?** *C Sanchez (Spain)*



---

---

PROGRAM

---

---

- 14.50 – 15.00 **Influence of leg compression treatment on cardiac function** Gy Szolnoky, et al. (Hungary)  
15.00 – 15.20 **Discussion**

**Thrombosis and anticoagulation** (Chair: PL Angitnani, Zs. Pecsarady)

- 15.20 – 15.30 **Can we prevent post-thrombotic syndrome using NOACs in acute venous thrombosis?**  
PL Antignani (Italy)  
15.30 – 15.40 **Treatment of high-risk pregnancies with tinzaparin** H Kiesewetter et al. (Germany)  
15.40 – 15.50 **DOAC treatment in fragile patients** Zs Pécsvárady (Hungary)  
15.40 – 15.50 **Management of acute thrombosis of greater saphenous vein involving saphenofemoral junction during pregnancy** S Xhepa (Albania)  
15.50 – 16.00 **Current practice for thromboprophylaxis in Hungary for varicose vein surgery** G Menyhei (Hungary)  
16.00 – 16.10 **Abdominal deep vein thrombosis profile in an internal medicine department: about 87 cases** Djama Mohamed-Lyes et al. (Algeria)  
16.10 – 16.20 **Deep vein thrombosis profile in a department of internal medicine: about 85 cases** Bounzira Tewfik (Algeria)  
16.20 – 16.35 **Discussion**

16.35 – 16.50 Coffee break

**Issues of venous circulation of the brain** (Chair: M Simka, F Schelling)

- 16.50 – 17.00 **Collapsibility of the internal jugular veins in the lateral decubitus body position: a potential protective role of the cerebral venous outflow against neurodegeneration**  
M Simka et al. (Poland)  
17.00 – 17.10 **Neuroinflammation and venous lesion of the neck veins in patients with Meniere's disease** A Bruno (Italy)  
17.10 – 17.20 **Glymphatic systems of the brain – physiology and possible role of this system in neurodegeneration** M Simka (Poland)  
17.20 – 17.30 **Cerebro-spinal venous insufficiency (CCSVI) and its possible consequences**  
F Schelling (Austria)  
17.30 – 17.45 **Discussion**

**19.15 – 22.30 Banquet, Hungarian Evening**  
*5 min walk. The meeting point is the exhibition area.  
Not included in the registration fee. Dress code: business casual)*

## Saturday 5 October

**Foam sclerotherapy** (Chair: F Passariello, I Rozsos)

- 8.30 – 8.40 **Venous-lymphatic malformations and treatment with foam sclerotherapy**  
PL Antignani (Italy)  
8.40 – 8.50 **Reasons of venous reflux mapping inaccuracies misleading treatment plannings in the US and how it can be improved** K Fattahi (USA)  
8.50 – 9.00 **Foam-washout sclerotherapy, a technique geared toward reducing short and long-term complications of regular foam sclerotherapy, and comparison with existing foam sclerotherapy method** K Fattahi (USA)  
9.00 – 9.10 **Diagnosis and Treatment of a 27 cm long symptomatic incompetent perforating vein at thigh level** K Fattahi (USA)  
9.10 – 9.20 **Medical grade plastic containers for oxygen and carbon dioxide to create sclerosing foam**  
A Cardenas (USA)  
9.20 – 9.30 **Does the extensive endovenous surgery, accelerate venous ulcer healing?**  
F Zernovicky (Slovakia)  
9.30 – 9.45 **Discussion**

**Glue treatment of varicose veins** (Chair: *K Bozkurt, A Szabó*)

- 9.45 – 10.00 **Invited speaker: K. Bozkurt (Turkey) The new n-butyl-2-cyanoacrylate glue ablation catheter incorporated with application guiding light for the treatment of venous insufficiency: Twelve-month results**
- 10.00 – 10.10 **Comparison of American and Turkish glue** *I Bihari et al. (Hungary)*
- 10.10 – 10.20 **Comparison of laser and glue in perforator vein treatment** *I Bihari et al. (Hungary)*
- 10.20 – 10.30 **Glue treatment of varicose veins** *A Szabó (Hungary)*
- 10.30 – 10.45 **Discussion**

10.45 – 11.00 Coffee break

**Servier symposium** (Chair: *F. Zernovicky, G Menyhei*)

- 11.00 – 11.10 **Pitfalls of writing guidelines for vascular diseases** *G Menyhei (Hungary)*
- 11.10 – 11.30 **Small saphenous vein reflux - how to treat it wise, not twice?** *F. Zernovicky (Slovakia)*
- 11.30 – 11.45 **Aesthetics of legs - latest aesthetic techniques, latest methods in chronic venous disease management.** *É Szabó (Hungary)*
- 11.45 – 11.50 **Discussion**

**Varicose veins and their treatment** (Chair: *A Flor, A Puskás*)

- 11.50 – 12.00 **Haemodynamic remodeling of vein wall** *Gy. Nádasy et al. (Hungary)*
- 12.00 – 12.10 **Prevalence of chronic venous disorders of lower limbs in Algeria: preliminary results** *B Malika et al. (Algeria)*
- 12.10 – 12.20 **Endovenous ablation of leg veins: should we be more or less radical?** *A Flor (Austria)*
- 12.20 – 12.30 **Pulsatile varicose veins of the lower limbs** *NM Bouayd (Algeria)*
- 12.30 – 12.40 **Viscosity estimates in chronic venous diseases** *F Passariello (Italy)*
- 12.40 – 12.50 **CHIVA-laser: office-based ambulatory hemodynamic procedure for conservative treatment of varicose veins** *A Puskás et al. (Romania)*
- 12.50 – 13.00 **Miniphlebectomy according to Várady's method as the mother of aesthetic phlebology** *J Kalemba (Poland)*
- 13.00 – 13.10 **Combination of EVLA, sclerotherapy and miniphlebectomy in treatment of recurrent varicose veins** *D Slavin et al. (Russia)*
- 13.10 – 13.20 **Honorary lecture: Z Várady (Germany) From traditional varicectomy to mini-surgery**
- 13.20 – 13.30 **Discussion**

13.30 – 14.15 Lunch break

**Aesthetic phlebology** (Chair: *Z Böhlm, MA Parikov*)

- 14.15 – 14.30 **Invited speaker: A Flor (Austria) Unwanted veins of the forearm and the hand: treatment options**
- 14.30 – 14.40 **Micro-“surgery” of spider veins** *Z Böhlm (Germany)*
- 14.40 – 14.50 **CLACS – The new modality in the treatment of teleangiectasias** *V Kovaics et al. (Slovakia)*
- 14.50 – 15.00 **Improved sclerotherapy by transillumination** *R Damisch (Austria)*
- 15.00 – 15.10 **Treatment of unaesthetic periorbital veins with 1064 nm long pulsed Nd:YAG laser** *MA Parikov et al. (Russia)*
- 15.10 – 15.20 **Venous insufficiency causing alteration of skin barrier function and microbiome protection** *J. Daróczy (Hungary)*
- 15.20 – 15.35 **Discussion**





**Endothermal surgery for varicose veins 2 (Chair: Ch Ragg, L Chernukha)**

- 15.35 – 15.50      **Application of thermal ablation in the treatment of patients with superficial vein thrombosis of lower extremities** *Shchukin et al. (Ukraine)*
- 15.50 – 16.00      **Laser crossectomy** *P Dragic (Serbia)*
- 16.00 – 16.10      **Hybrid AASV-GSV vein: incidence and anatomical pattern** *O Riabinska et al. (Ukraine)*
- 16.10 – 16.20      **Endovenous treatment of post-surgical varicose vein recurrency** *I Bihari et al. (Hungary)*
- 16.20 – 16.30      **Modern opportunities of endovascular techniques in solving the problem of pelvic pain. When, why, how?** *L Chernukha et al. (Ukraine)*
- 16.30 – 16.40      **Eight years of non-saphenous vein endovenous laser ablation with radial fiber** *MA Parikov et al. (Russia)*
- 16.40 – 16.50      **The role of echo-guided foam in varicose ulcer treatment.** *Isaac Yopan (Mexico)*
- 16.50 – 17.05      **Invited speaker: L Chernukha et al. (Ukraine) Possibilities of endovenous laser coagulation in the treatment of patients with congenital abnormalities of the deep venous system of the lower extremities**
- 17.05 – 17.15      **Discussion**
- 17.15 – 17.30      Coffee break

**Closing remarks**

- 17.30 – 17.40      **Quo vadis (endo)venous surgery** *I Rozsos (Hungary)*
- 17.40 – 17.55      **Invited speaker: Ch Ragg (Germany) Crossroads in phlebology**
- 17.55 – 18.10      **Invited speaker: R Milleret (France) Return to the future: 50 years of vascular ultrasound**
- 18.10              **Awards prizes (Best Presentation, Best Mini-phlebectomy Presentation, Best Glue Presentation)**

*Length of most presentations is 8 minutes, followed by a 2 minute discussion.*

*At the end of each session there is a further possibility to discuss the papers presented.*



# Abstracts

## WHAT DOES 'ANOTHER PHLEBOLOGY' MEAN?

Imre Bihari

*A+B Clinic, Budapest, Hungary*

Another Phlebology means something different from the widely used, everyday diagnostic and therapeutic practice. Another Phlebology is a continuously changing collection of topics. Five decades ago it was hook phlebectomy, four decades ago valvuloplasty of the deep veins, three decades ago endoscopic perforator vein surgery, two decades ago foam sclerotherapy and laser and radiofrequency ablation, one decade ago NOACS which were subjects of another phlebology. Nowadays Another Phlebology topics are the content of this meeting. As they become part of everyday routine they are not part of Another Phlebology any more. For example laser ablation of varicose veins is not part of this, but laser ablation of perforator veins and recurrent varicosities is.

Not only new developments belong here, but there are further aspects of Another Phlebology: techniques which are regularly being used, but only by a few experts, like CHIVA or valve replacement surgery.

We would like to give increasingly better examination and therapeutic methods to our patients. Our subject is this continuously changing collection of possibilities.

Our partners are manufacturers, scientists, medical colleagues who constantly find new things to help prevent and heal venous diseases. We can rely on them that with their help we will have subjects for future Another Phlebology meetings.

## EUROPEAN DIPLOMA OF PHLEBOLOGY

Spyros Vasdekis

*Member of the European Board of Phlebology, Greece*

Phlebology in European countries is practised by different specialties and under different conditions. The UEMS is a non-governmental organization representing national associations of medical specialists at the European Level. With a current membership of 37 national associations and operating through 43 Specialist Sections and European Boards, the UEMS is committed to promote the free movement of medical specialists across Europe while ensuring the highest level of training. Following the application of 4 Specialist Sections (Vascular Surgery, Radiology, Dermatology and Surgery) a Multidisciplinary Joint Committee

on Phlebology (MJCP) was formed in 2014. Three years later the MJCP applied for the creation of a European Board of Phlebology (EBP) which was approved by the Council of UEMS as a certification authority in Phlebology. The EBP produces European Training Requirements and Curriculum in cooperation with national Phlebology Societies and recognizes centers of training. Following appropriate training doctors can take examinations in the EBP and obtain the European Diploma of Phlebology. The Diploma is a recognition for the doctor of his/her high level of training that meets European standards. It is suggested that all the EE countries should participate in MJCP and EBP in order to achieve the higher standards in Phlebology.

## TRAINING PATH FOR EUROPEAN PHLEBOLOGISTS

Daniela Radu

*Department of Surgery, University of Medicine and Pharmacy "Victor Babes" Timisoara, Romania*

*Background:* Until today, implementation of the EU VET tools and recommendation has not been carried out in the field of Phlebology and therefore no harmonized training standards, qualifications and VET accreditation are available. This depends on the fact that this discipline, which deals mostly with the treatments of venous and lymphatic disorders, although fully recognized, does not have specific specialization courses in most of the Member States; on the contrary, education and training in topics connected to phlebology are often included in courses which have a wider scope.

*Aim:* We will create the first EU-wide classification and characterization of skills, qualifications and competence in the area of Phlebology. These qualifications will be built by a new VET EU-wide curriculum based on learning outcomes, with transparency and recognition tools.

*Method:* Several countries were represented in this project by colleagues with activities in the specific field of Phlebology and we began the first drafts for the approval of a Project at the level of the European Commission: Romanian Society of Phlebology, Registro Europeo dei Flebologi, Hellenic Society of Dermatologic Surgery, Europe Vein Center, Associazione Flebologica Italiana, P.R.A.IT Soc.Coop., Europartners S.R.L., European Health Chamber.



*Conclusions:* This project contributes to the establishing a first European training and accreditation path for doctors practising phlebology. For the first time, a standard EU wide training frame will harmonize the current fragmentation and steps for the formal recognition of the Phlebologist inside the medical profession have been launched.

### TREATMENT OF VARICOSE VEINS WITH MICROWAVE

István Rozsos<sup>2</sup>, Gergely Vadász<sup>1,2</sup>, Melinda Gadácsi<sup>1,2</sup>

<sup>1</sup>University of Pécs, Department of Vascular Surgery, Pécs, Hungary

<sup>2</sup>Theta Center Budapest & Pécs, Hungary

*Background:* Operation technique of varicose veins has been evolved spectacularly by endovenous solutions in the last 15-20 years. Incisions got smaller by time, but the main step of the traditional open surgery remained the mechanical removal of the saphenous vein by stripping even with cryovaricectomy. This method caused surrounding tissue damage – which was the main goal to avoid by developing novel techniques. Endovenous laser (EVLA) and radiofrequency ablations (ERFA) ment the new era in the treatment of varicose veins. Based on thermal ablation of the veins, the race between the improving laser and radiofrequency techniques result in that not only efficiency, but patient safety has been progressed in time. Avoiding thermal damage, glue-based sealing technique has been developed as well, and started to gain ground. Besides evolving therapy even diagnostic methods have been progressed from huge, poor resolution sonography devices to compact, one-handed wireless tools, easy to use even with mobile IT devices.

*Aim:* After 13 years the first endovenous operation in Hungary, we have seen the evolution of the technique through the experience of over 1700 EVLT surgeries. Decreasing thermal damage became the target of the race between endovenous methods, since all further complainings are connected with this side effect. The latest innovation on this field is based on microwave technique (MwVAS). This system has a good thermal penetrability and high efficiency and the lower temperature (80 C°) at the tip of the microwave probe rarely causes perforation of the vein wall comparing with EVLA and EVRA, therefore - with the same treatment effect and recovery period - fewer postoperative complications are feasible.

*Method:* From November 2018 to April 2019 11 cases were assigned to microwave ablation as the first MwVAS interventions in Hungary (22 limbs total - 11 limbs for the microwave group, 11 limbs for the control EVLT group). The visibility of microwave antenna was powered by Landwind Medical MINO wireless color doppler ultrasound system which is easy to pocket, connects and shows high resolution image on a mobile phone, tablet PC, laptop PC, even smart TV. We compared the results considering

side effects (operating time, hospital stay, ecchymosis, burning sensation, postoperative swelling, aesthetic difference) based upon a patient completed survey.

*Results:* There was no significant difference in operating time and hospital stay in the two groups. Ecchymosis and burning sensation was slightly lower in the microwave ablation group. Further results as the recanalisation – occlusion rate are requiring further follow-up investigations.

*Conclusion:* Microwave ablation system is a safe and effective alternative to other endothermal ablation methods without serious complications and better cosmetic results. Therefore, as our knowledge increases with the novel diagnostic and endovenous devices so they are shrinking in sizes.

### CRYO FIBROSIS OF SAPHENOUS TRUNKS

R. Milleret

Vichy - France

*History:* Introduced in clinical practice as early as 1977, cryo-sclerosis was the first endovenous technique. Its aim was to offer a more efficient option than high ligation of the sapheno-femoral junction when general anesthesia was inadvisable. We combined high ligation with freezing the vein wall using a long cryode whose tip was cooled at -90° Celsius. The whole procedure was performed under local anesthesia. The introduction of heating techniques 20 years ago supplanted cryo-sclerosis and cryo-stripping. But cryo-sclerosis, now re-named cryo-fibrosis may again become a valuable option. Recently the Hungarian team published good results using my original technique.

*Technical improvements:* Endovenous methods have proved that high ligation is rarely necessary when ablating a saphenous trunk. But the old cryo probes were rigid and with a diameter of 3.5 mm difficult to introduce from under the knee or from the ankle, and furthermore an incision and a phlebotomy were necessary. Flexible cryodes with a diameter of 1.9 mm are now available, they can easily catheterize the saphena through a F6 introducer. The freezing tip was only 1 cm long, so we froze only 1 cm every 5 cm, leaving intact endothelium segments which induced recanalization. We now use 5 cm freezing sections, thus the whole length of the trunk can be cooled in a reasonable amount of time, comparable to the Venefit® procedure.

*Pilot study:* We performed a pilot study on 10 patients. At 6 months all the vein were closed along their full length. No adverse effect was reported. Longer follow up and more cases are under way.

*Advantages:* The procedure does not need tumescent anesthesia. Post operative inflammatory reactions are minimal. The probe can be re-sterilized with the usual steam devices found in every surgical facility which will considerably reduce the cost per procedure, allowing many patients in developing countries to benefit from endovenous techniques.



### ENDOVENOUS WELDING IN MINIMALLY INVASIVE TREATMENT OF CHRONIC VENOUS DISEASES

L.M. Chernukha<sup>1</sup>, V.S. Horbovets<sup>2</sup>, S.I. Savolyuk<sup>2</sup>,  
O.O. Dyadyk<sup>2</sup>, V.A. Khodos<sup>2</sup>, M.V. Chekhlov<sup>3</sup>,  
R.A. Gerashchenko<sup>2</sup>

<sup>1</sup>National Institute of Surgery and Transplantology named  
after A.A. Shalimov of NAMS of Ukraine

<sup>2</sup>National Medical Academy of Postgraduate Education  
named after P.L. Shupyk, Kyiv, Ukraine

<sup>3</sup>Odessa National Medical University clinic, Odessa, Ukraine

**Background:** The problematic aspects of application of thermal ablation methods in the treatment of chronic venous diseases (CVD) induced the search for alternative technology with less tissue heating and a more perfect algorithm of management of energy. Our opinion the method of endovenous welding (EVW) is better, which means an ablation executed by denaturation of venous wall under the influence of high-frequency modulated current with automatic generation of parameters.

**Aims:** To determine the opportunity to use and study the results of the endovenous welding in the treatment of patients with chronic venous diseases.

**Patients:** EVW was used during 40 operations of 26 patients with CVD C3 – C5 (9 men and 17 women aged from 30 to 65). EVW of the vena saphena magna (VSM) was performed in 34 cases, vena saphena parva (VSP) in 6. The diameter of the VSM and VSP junction segments ranged from 12.8 to 24.3 mm and from 6.2 to 9.4 mm, respectively. Criteria for evaluating the results: the intensity of postoperative pain (PP), ultrasound (US) data after 1, 3 and 6 months, the presence or absence of complications.

**Methods:** The device for an EVW includes a generator EK 300M (Svarmed, Ukraine) and a welding instrument (WI) with a working part in the form of a bipolar configuration of electrodes with a diameter of up to 3 mm and a length of up to 5 cm (fig. 1 – 2). Duty cycle (DC) of welding is performed at a voltage from 10 to 100 V, frequency-alternating current from 50 to 500 kHz, with modulation from 0.1 to 250 kHz, with tissue resistance from 0.1 to 1000 Ohm. The duration of the DC shall be determined by the coefficient of relative resistance in accordance with the formula:  $k = R_i(t_i)/R_0(t_0)$ , where  $R_i(t_i)$  – flow resistance,  $R_0(t_0)$  – initial resistance. Upon reaching the certain value of  $k$ , the device finishes the WC.

The impact of the EVW has been studied during bench tests on 16 remote segments of the VSM with a diameter of 4.5 to 23 mm. Data of recording the dynamics of electrical parameters and temperature were processed using the Matcad software package. Staining with hematoxylin and eosin, according to Van Gieson and staining for elastic fibers (Elastic Stain Kit) were used for pathomorphological studies.

EVW was performed in accordance with generally accepted methods: puncture of the vein under US control,

import and positioning of the WI, tumescent anesthesia. In the VSM junction the distal pole of working part of the WI was positioned on the level of the v. epigastrica, in the VSP junction – 1 cm from the popliteal vein (fig. 3). Ablation was performed sequentially in each part of a vein at lengths of 5 cm.

**Results:** During bench studies, ablation of each vein area was performed within 5 to 12 seconds and was accompanied by heating to 55 to 80 °C (fig. 4). Completion of the DC occurred at the time of the development of denaturation of the venous wall, regardless of the diameter of the vein and the volume of residual blood in its lumen (fig. 5). Damage to paravasal fatty tissue was not observed after performing repeated DC (fig. 6).

Pathomorphological studies have established the alteration of the venous wall mainly to the depth of the inner and middle layers in the form of endothelial coagulation, destruction and homogenization of collagen and smooth muscle fibers, adventitia detachment (fig. 7 – 9).

The development of US signs of ablation was observed during operations in the course of the DC (fig. 10). Absence of PP was detected among 17 (65.4%) patients. 9 (34.6%) patients had moderate PP. During 1 month all patients had obliteration of target vein segments, and 7 patients (26.9%) had certain areas of fibrosis; after 3 months fibrosis of vein segments was detected among 12 (46.2%) patients (fig. 11 – 12). After 6 months, fibrosis of target vein segments was detected among 26 (100%) patients with an US picture of a “thermal crossectomy” (fig. 13). All patients had a satisfactory cosmetic result; no complications were detected (fig. 14).

**Discussion:** The EVW method demonstrated controlled ablation in 100% of cases, including among patients with large vein diameters. It was shown that, unlike other methods of thermal ablation, EVW provides minimal tissue heating and prevents burns and paresthesias. However, a limited number of patients and a short observation period determine the need for further research.

**Conclusions:** 1. EVW allows performing the controlled electro-thermal ablation of the veins to be performed based on denaturation of the components of the venous wall.

2. The first results of the clinical application of EVW are encouraging: fibrosis of the VSM and VSP during the observation period of 6 months and a satisfactory cosmetic result were obtained in 100% of patients.

3. The automatic control mode of the DC provides for a relatively low heating of the veins and paravasal tissues, and eliminates the influence of subjective factors on the ablation results, which makes it possible to use the EVW for large diameter veins.



**EXTRACORPOREAL  
HIGH-INTENSITY-FOCUSED-ULTRASOUND  
(HIFU) TREATMENT  
OF VARICOSE VEINS – FIRST IN HUMAN STUDY**

Alfred Obermayer

*Institute for Functional Phlebo-Surgery, Melk, Austria*

*Background/Aim:* HIFU is a well-established alternative to surgery or other thermal methods widely used for prostate, thyroid, breast fibroadenoma, bone metastasis, essential tremor or uterine fibroma treatment. A first in human prospective open study - approved by the competent Austrian authorities - followed patients treated for incompetent lower limb veins up to 3 months (M).

*Methods:* The Echopulse Theraclion device generates HIFU which penetrates through soft tissues and causes localized hyperthermia (around 85°C) responsible for irreversible protein denaturation and vein wall coagulation while overlying and surrounding tissues are spared, by focusing a beam onto a defined target. A focused piezoelectric transducer (3 MHz resonant frequency) engenders the ultrasound field. At the center of the transducer, an imaging array of 7.5 MHz is integrated to allow perfect real-time imaging alignment of the focal point. No adjunctive methods were allowed during follow-up.

*Results:* We have several interesting examples of positive results after 3M follow-up. About a third of cases were performed without anesthesia, were well tolerated and no severe adverse events were observed. None of the patients presented scars or skin pigmentation. The degree of vein tortuosity was a non-issue and no anticoagulants were used.

- A) A female patient presented recurrence after GSV (Great Saphenous Vein) stripping. No anesthesia was performed. The treated area was acutely occluded and this result is persistent at 3M.
- B) A female patient (72 years old) presenting a stump refluxing and neovascularization after GSV stripping as well as an active ulcer was treated at the groin level – over the stump and neo-vessels area. No anesthesia was given. The recurrent flow was abolished and the ulcer was healed at 3M.
- C) A male patient (95 years old) presenting severe skin disorders and painful small exsuding ulcers at the medial lower leg, caused by an insufficient perforator, located directly below. At 3M the perforator was occluded, the ulcers healed, the pain was resolved.
- D) A female obese patient (76 years old) presenting a refluxing GSV. Tumescence anesthesia was given. The vein was acutely occluded and this result persisted at 3M. The ultrasound findings 3M later are similar to intraluminal thermoablations such as LASER, RF.

*Conclusion:* In this first study using HIFU for incompetent lower limb veins, the preliminary results are encouraging and show that this method could become a convincing, innovative and patient-friendly alternative non-catheter treatment method in this field. More cases and longer follow-up will be required in forthcoming studies.

**UGLA – ULTRASOUND GUIDED  
LASER ABLATION**

Petar Dragić, Srdjan Andrić, Saša Bralušić, Jelica Malešev,  
*„Dr Dragić“ clinic for laser vein operations,  
Novi Sad, Serbia.*

*Background:* Endovenous laser ablation (EVLA) is a commonly used and very effective minimally invasive therapy to manage leg varicosities. Even though the use of laser in phlebology is spreading ever wider, there is still no uniformity and general consensus about how the laser energy should be apportioned for the best outcome and what parameters should be taken into consideration. Most practitioners use a fixed Linear Endovenous Energy Density (LEED), which is based on laser power output and continuous speed of retraction, while only sometimes adjusting the value according to vein diameter. Measurements and practice show wall thickness often varies throughout its length and does not always correspond proportionally to vein diameter and this is often not taken into consideration when calculating LEED.

In this study we analyze and present our results with a goal to find a way to best utilize all available knowledge. We also stress the importance of real-time adjustment of factors and the importance of continuous ultrasound monitoring to achieve this.

*Methods:* 100 consecutive legs with insufficient GSV were selected in a prospective cohort study, while age, gender and diameter of GSV were not determining factors for exclusion or inclusion. All patients were scanned prior, during and two months after the surgery using a GE LOGIQ V2 ultrasound machine with a 5-12MHz linear probe. Operations were conducted using a BioLitec Leonardo 1470nm laser with a radial-tip fiber. Out of 78 legs which were determined to have varying vein wall thickness, half were treated with a uniform LEED, while the other half were treated by real time adjustment of speed retraction to consequently adjust LEED, according to visualized changes in vein wall thickness.

*Results:* Out of 100 legs, 78 (78%) proved to have varying GSV wall thickness throughout their length. The etiology of these thickenings was found to be postthrombotic changes, varicosities, aneurysms or of unknown origin. Out of 39 which were treated by uniform LEED 2 (5%) had recanalization and 18 (46%) had thrombus formation rather than fibrosis at spots where the vein wall was thicker, resulting in postoperative pain or discomfort.



*Conclusion:* Ultrasound guided laser ablation yields superior results because continuous monitoring of the EVLA process allows real-time correction of laser fiber retraction speed, thus adjusting LEED to match thickness of vein wall, which is often not equal throughout length of the veins. Adjustable speed of retraction generally gives better results when compared to retracting the fiber at equal velocity at all times.

### **HISTOLOGICAL CHANGES FOLLOWING CLOSURE FAST TREATMENT**

Karin Brachmann, Uwe Guetz

*Center of Vascular Medicine, Leipzig, Germany*

*Introduction:* In Germany, crosssection following the Babcock procedure and stripping of the great saphenous vein were considered as the „gold standard“ in varicose treatment since 1907. Only in the late nineties of the last century was a new and less invasive treatment of varicose vein developed: endovenous obliteration. It was our intention to make a contribution towards objectivizing the results after the Closure FAST® therapy.

*Methods:* In our tests we made a mini-incision to remove a part of the great saphenous vein after radiofrequency treatment with the Closure FAST® catheter for histological examinations.

*Results:* In all our patients we found the same alterations: a complete destruction of the intima layer, a denaturation of the collagen and a subintimal edema. After 4 months we saw a complete obliteration of the vein and a thrombus in organisation with an immigration of granulocytes in the tissue.

*Conclusions:* After the Closure FAST treatment of varicose veins in 102 patients we have the histological proof for the destruction of the intima and the collagen with necrosis and destruction of the vessel wall. The result is the complete obliteration which was confirmed by Duplexscan and MRT after 1 year. A detailed statistical analysis of one's own patient population is presented 9 years after the treatment.

### **THE USE OF LASER THERMOABLATION FOR THE TREATMENT OF INCOMPETENT PERFORATOR VEINS – LATE RESULTS**

Witold Woźniak<sup>1</sup>, Michał Świder<sup>1</sup>, R. Krzysztof Mlosek<sup>2</sup>,  
Piotr Myrcha<sup>1</sup>, Piotr Ciostek<sup>1</sup>

<sup>1</sup> *First Chair and Clinic of General and Vascular Surgery,  
Second Faculty of Medicine, Medical University  
of Warsaw, Poland*

<sup>2</sup> *Department of Diagnostic Imaging, Second Faculty  
of Medicine, Medical University of Warsaw, Poland*

A natural derivative of the success that had been achieved in the treatment of varicose veins with intravenous thermoablation was the use of these techniques in the treatment of perforator venous insufficiency.

*The aim* of the study was to evaluate the efficacy and safety of intravenous thermoablation with a 980nm laser of perforator veins.

*Material and method:* In 2013-2015, 55 patients were operated on (42 women and 13 men) aged 29-85 (mean age 52.9, SD 14.4). Only patients with isolated insufficiency of perforator veins qualified for the research group. Taking into account the severity of the disease according to CEAP clinical classification, the distribution of patients was as follows: C2-9 (34.5%), C3-8 (14.6%), C4-18 (32.7%), C5-7 (12.7%) and C6-3 (5.5%). In total, 67 perforator veins were treated with thermoablation, operating in 46 patients (83.6%) one perforator, in 6 patients (10.9%) two perforators and in 3 patients (5.5%) 3 perforators. Thermoablation was performed under tumescent anesthesia with 6-12W power, using 5-6 pulses for each 0.5-cm vein segment. The energy range for a single perforator was 66-656J (average 201.1J). The assessment of the effectiveness of treatment was based on the VCSS index, the value of which was calculated before surgery, 6 and 36 months afterwards. Regular clinical and ultrasound scans were performed every 6 months.

*Results:* On the day of discharging the patient home, all perforators subjected to thermoablation were occluded. Among complications local ones dominated: surgical site sclerosis and subcutaneous hematoma (40.4%), prolonged postoperative pain (10.5%), paresthesia (7%), superficial vein inflammation (5.3%) and skin burn (1.8%). No general or thromboembolic complications were noted. The recanalization rate after one year was 19.4% and amounted after 2 years to 23.3% and after 3 years to 26.3%. The mean VCSS before surgery was 6.65, after 6 months it was reduced to 2.91 and after 3 years it remained at a reduced level - 3.28.

*Conclusion:* Laser thermoablation is a safe and effective method of treatment of incompetent perforator veins.

### **1- YEAR RESULTS OF ENDOVENOUS LASER THERAPY WITH LONGER WAVELENGTH (1940 NM) AND LESSER ENERGY DENSITY (LEVEL2 Study)**

Thomas Schmitz-Rixen<sup>1</sup>, Slobodan Dikic<sup>2</sup>, Abhay Setia<sup>2</sup>,  
Mircea Marius Tipi<sup>2</sup>, Sahit Demhasaj<sup>2</sup>, Ronald Stroka<sup>3</sup>,  
Claus-Georg Schmedt<sup>2</sup>

<sup>1</sup> *Klinik für Gefäß- und Endovaskularchirurgie, Klinikum  
der Goethe Universität, Frankfurt am Main, Germany*

<sup>2</sup> *Klinik für Gefäßchirurgie, Diakonie-Klinikum,  
Schwäbisch Hall, Germany,*

<sup>3</sup> *Laser-Research-Laboratory (LFL) im LIFE Zentrum,  
Klinikum der Ludwigs-Maximilians-Universität, München*

*Introduction:* The LEVEL1 Study with the longer wavelength (1940 nm) and higher energy density (30-90 J/cm) carried out at our center showed promising results with high efficacy, a better risk profile and improved patient



comfort. It is postulated that because of the higher absorption of the longer wavelength in water, the treatment would be equally effective with lower energy densities. We studied if, with a reduction of energy density, a significant reduction in the incidence of thermal nerve injuries with dysesthesia can be achieved, without impairment of the efficacy of the elimination of reflux in treated truncal veins.

**Methods:** This prospective observational study was conducted between 23.6.2017 - 22.1.2019 to evaluate Endovenous Laser Therapy (EVLT) using a long wavelength (1940 nm) laser with a radial fiber. The energy density according to the standardized protocol was 20-40 J/cm. Simultaneous procedures like mini-phlebectomy (Varady) were performed as adjuncts. A standardized questionnaire, clinical examination and color doppler sonogram were carried out preoperatively and postoperatively after 3 days, 4 weeks, 6 months and 12 months. Data pertaining to demography, venous anatomy and morphology, LEED (longitudinal endovenous energy density), duplex findings and complications were collected and documented.

**Results:** We studied 173 EVLT Procedures (Tm, 1940 nm, Radial Fiber) 102 females (n=102) and 71 males (n=71). The average preoperative diameter of the great saphenous vein (GSV n=137) was 7.1 mm and of the small saphenous vein (SSV n=36) 5.6 mm. The LEED in thigh region was 40J/cm, the LEED in the region from patella up to proximal leg was 30 J/cm and in leg region was 20 J/cm. Postoperative Examinations were carried out at 1-4 weeks (100%) and at 6-12 months (66%, 114/173). In the early postoperative phase (1-4 weeks), the following complications were observed: Localized paresthesia in 1.7% patients (3/173), Post Ablation Thrombus Extension (PATE) in 1.4% cases (2/173). No other complications were observed in this period. The postoperative pain intensity on the Visual Analog Scale (VAS 0-10) averaged 0.4 (0-4). In the late postoperative phase, localized paresthesia was documented in 3.5% of cases (4/114). PATE and chronic persistent pain was not observed. A full closure of the vein was present in 95.6% (109/114) of the treated truncal veins.

**Conclusion:** The EVLT with longer wavelength (1940 nm) is highly effective even with a lower energy density (20-40 J/cm). With this strategy, the incidences of thermal nerve lesions can be reduced to a minimum. With meagre postoperative pain, patient comfort is at its peak.

**VARICOSE VEIN RECURRENCY SCORE SYSTEM FOR LASER SURGERY**

Imre Bihari  
A+B Clinic, Budapest

**Introduction:** Equipments, patient conditions and surgical techniques has an important influence on the mid and long-term results of varicose vein surgery. In these factors only equipment is studied widely. Laser surgery has been performed by us for 12 years. In the last 9 years we have

not carried out classic varicose vein surgery, only laser surgery. More than half our patients had some special conditions which influence the long-term results of varicose vein surgery. These patients are usually excluded from other studies. Some surgical techniques also have a crucial role in the recurrency rate.

**Aim:** To calculate the rate of recurrency after varicose vein laser surgery.

**Patients:** In the last 12 years 2048 laser surgery has been performed. The age range was between 14 and 82 years, women:men=72:28. The diameter of the saphenous veins (GSV 82.8%, SSV 12.5% and AASV 4.5%) was between 4 and 32 mm. CEAP C2-6, VCSS mean 6.3. 64% of our patients could be followed for longer than 1 year and 43% longer than 4 years.

**Methods:** Different patient conditions and surgical techniques were evaluated regarding their influence on recurrency rate. According to recurrency percentage, points were given to different risk factors.

**Results:** One point means 10 % probability of recurrency within 4 years.

No	Reasons of recurrency	Our statistics %	Recommended point
1.	Venous malformation	100	10
2.	Cardiac decompensation	100	10
3.	Earlier deep venous thrombosis	52	5
4.	Delivery after surgery	38	3
5.	Diameter of GSV more than 12 mm	28,5	2
6.	BMI > 35	19	1
7.	Double saphenous stem insufficiency	14.3	0.5
8.	Recurrency after earlier surgery	12.1	0.5
9.	Demanding work or sport	9.1	0.5
10.	Keeping insufficient SFJ	46	4
11.	Keeping thigh part of insufficient GSV	24	2
12.	Keeping insufficient perforator vein	19	1
13.	No factor	6.5	1

**Conclusions:** In our opinion it is important to judge in advance the probability of mid and long-term recurrency results. It seems that patient conditions and some technical details have more influence on the results than the equipment. This calculation will enable us to get a better idea of our expectations, and inform our patients in advance about the probability of recurrency.



### ENDOVENOUS ABLATION OF FEEDING VEIN IS A GOOD CHOICE OF THERAPY FOR PATIENTS WITH VENOUS LEG ULCER

Tanja Planinšek Ručigaj, Matjaž Vrtovec,  
Aleksandra Bergant Suhodolčan

*Dermatovenereological Clinic,  
University Medical Centre Ljubljana, Slovenia*

*Aim:* Venous leg ulcers often fail to heal despite good compression therapy. In such patients endovenous ablation of feeding veins is good choice for therapy.

*Method:* In a clinical trial 6 patients (4 men, 2 women) with 6 venous leg ulcers, were included. 4 of them had venous insufficiency on the left leg, 2 on the right. Average ulcer duration was 17.2 years. Average ulcer size was 72.5 cm<sup>2</sup>. Wound beds were estimated as B-A2 by V. Fallanga classification before endovenous procedures. Endovenous procedures with EVLA and foam sclerotherapy were performed.

*Results/Discussion:* After endovenous procedures all ulcers were completely healed in between 3 and 6 months. No major complications were observed during treatment.

*Conclusion:* Ablation of the insufficient venous system provides an effective treatment option for long-lasting, non-healing venous leg ulcers and can be safely used when the non-infected ulcer is still present.

### SHAVE-THERAPY WITH SIMULTANEOUS AUTODERMOPLASTY FOR PATIENTS WITH EXTENSIVE TROPHIC ULCERS

Sergey Yakushkin, Ilya Sorokvasha  
*Semeynaya clinic, Moscow, Russia*

*Objectives:* Due to the recent increase of the rate of patients with large size trophic ulcers or conservative therapy ineffectiveness it has become necessary to apply invasive methods to trophic ulcers. One such method is a layered tangential suprafascial necrosectomy and fibrosectomy also known as Shave-therapy in combination with autodermoplasty.

*Materials and methods:* During the last 12 months 17 patients with venous trophic ulcers were operated on, 10 of them had ulcers against the background of varicose veins and 7 suffered from post-thrombotic disease.

*Patients' profile:* 5 male and 12 female. Average age 62.7 ± 5.9 years. Average trophic ulcer size 204.4 ± 12.9 cm<sup>2</sup>. Average trophic ulcer existence duration 4.67 ± 4.8 years. All patients were operated on using the method of layered tangential suprafascial necrosectomy and fibrosectomy also known as Shave-therapy in combination with autodermoplasty. An 0.3 mm skin flap was removed from the affected limb thigh using electrodermatome. Shave therapy was applied to all patients, regardless of the wound process stage until bleeding surface appearance, each removed layer thickness was 0.2-0.4 mm. A surgical stapler

was used to staple skin flaps. In order to avoid under-flap hematoma formation several skin flap perforations were done with a scalpel. For the lower extremity compression an inextensible bandage was used. Surgical procedures were performed in a round-the-clock hospital. In 13 cases patients were under endotracheal anesthesia and in 4 cases under spinal anesthesia. In 10 cases, in addition to other manipulations, EVLA (endovenous laser ablation) was simultaneously performed in order to eliminate venous reflux.

*Results:* when evaluating the results, skin flap adaptation on the wound was examined in the first 12 days, then in 20 and 30 days. On the 12th day in all patients no skin flap lysis was observed. On the 20th day, marginal lysis of the flap was detected in two cases. On the 30th day all patients had almost full healing of wounds.

*Conclusion:* Thus layered tangential suprafascial necrosectomy and fibrosectomy also known as Shave-therapy in combination with autodermoplasty is an effective, modern extensive venous ulcer patient treatment method, which allows you to close extensive wound defects without preliminary preparation.

### WOUND CARE PRACTICES FOR INFECTED VENOUS LEG ULCERS AND PRUDENT USE OF ANTIBIOTICS

Roy Varghese<sup>1</sup>, Malay Patel<sup>2</sup>, Manjusha Rajarshi  
<sup>1</sup>Daya Hospital, <sup>2</sup>First Choice Vascular Centre, India

*Introduction:* The cornerstone of treatment for venous leg ulcers (VLU) is compression therapy that helps in symptom control, local wound environment and promotes healing. However, chronic VLUs of more than 6 weeks with other co-morbidities like diabetes, hypothyroidism and auto-immune vascular disorders pose clinical challenges. Nosocomial infections & poor wound care practices contribute to poor prognosis and clinical outcomes. In this study compression and local wound care management and if required in some cases the use of systemic antibiotics was considered.

*Materials and Methods:* Patients with chronically infected ulcers from January 1, 2016 to December 31, 2017 were included in this study. Infection was assumed in wounds exceeding 6 weeks, having exudate, raised leukocyte count, signs of local inflammation, oedema, lymphangitis and disproportionate pain not responding to compression bandages with Vaseline-sucrose dressing that were changed depending on strike-through. Blood samples and tissue fluid aspirate surrounding the ulcer area were collected for bacteriology from the suspected cases of systemic infection. Patients received appropriate systemic antibiotic cover based on culture sensitivity reports. Patients with co-morbidities received optimal treatment. Admitted patients were given foot elevation, compression bandage, micronized purified flavonoid fraction and change of dressings as needed.





**Results:** Results from 813 patients are presented; further enrolment is continued. Gram-negative flora accounted for the majority of infections (E.Coli 10.3%, Acinobacter 3.5%, Klebsiella 9.25%, Proteus 8.1%). Staphylococcus 29.8% was the other common organism. Antibiotics were required in patients with septicaemia, acute local inflammation, severe pain and hepato-renal dysfunction. Antibiotic treatment was initiated only in confirmed multi-resistant systemically infected patients; in other cases the treatment protocol was restricted to Vaseline-sucrose bandages, compression and controlling the co-morbidities. The use of antibiotics was very prudently handled. Modified Gritti-Stokes amputation with partial closure was done in 8 patients presenting with arterial ischemia, gangrene and sepsis. 3 patients died during the 28-day postoperative period. All others moved towards showing appearance of healthy granulation within first two weeks.

**Conclusions:** VLU of one-third of the patients were infected with multi-resistant pathogens. Use of water from contaminated water bodies, poor quality tap water for wound washing and inappropriate use of antibiotics contributed to the poor prognosis of venous ulcers. In this study, we modified the treatment with the use of sterile solutions for wound washing and use of appropriate antibiotics. Ulcers of more than 6 weeks should be sent to specialised wound care centres. Public healthcare measures must aim to improve water quality. All healthcare centres must be educated prudent and rational use of antimicrobials.

**ROLE OF VITAMIN D3 IN THE MANAGEMENT OF PAIN IN C5- 6 CHRONIC VENOUS DISEASE (CVD): NEED TO INCLUDE AS AN INTEGRAL PART IN THE TREATMENT PROTOCOL**

Roy Varghese<sup>1</sup>, Malay Patel<sup>2</sup>, Manjusha Rajarshi  
<sup>1</sup>Daya Hospital, <sup>2</sup>First Choice Vascular Centre, India

**Introduction:** Vitamin D deficiency prevails in epidemic proportions all over the Indian subcontinent, with a prevalence of 70%-100% in the general population. Despite adequate sunshine, sub-clinical vitamin D deficiency is highly prevalent in both urban and rural settings across all socioeconomic and geographic strata. Vitamin D deficiency affects several aspects of health and its supplementation is known to benefit health. Leg ulcers secondary to chronic venous disease (CVD) are common and prevalent in the adult Indians. Non-compliance for treatment and lifestyle measures lead to worsening of the disease causing significant morbidity. Although the treatment is multi-faceted, it has high recurrence and failure rates often requiring surgical intervention in the worst progressed cases. The current available clinical evidence is suggestive of improvement in wound healing in patients with venous leg ulcers with supplementation of micronutrients, vitamin D and folic acid. Vitamin D supplementation for better clinical outcomes in CVD

patients was considered as a treatment protocol in an out-patient setting in this study.

**Objective 1:** To evaluate the prevalence of Vitamin D3 deficiency among CVD patients presenting CVD of CEAP C5- 6.

**Objective 2:** Evaluation of pain score at baseline and post treatment in CVD patients using Villalta score and patient feedback to the treatment.

**Objective 3:** To evaluate the safety and clinician's assessment of the treatment

**Methods:** This was an open study in an out-patient setting. 400 out-patients of both genders were enrolled in this study during the year 2016-17 and were evaluated for CVD using the CEAP classification system. The treatment protocol was standardized for all patients presenting with pain. The standard treatment included below-knee compression with oral amitriptyline, 5 mg morning & 10 mg evening and micronized, purified flavonoid fraction 1 gm daily. Patients with pain at the end of 1 week received twice the dose of amitriptyline. Serum Vitamin D3 levels were estimated at baseline and the deficiency was treated with intramuscular injection of Vitamin D3, 600,000 IU once weekly for 4 weeks. Patients were followed up at day 15 and weekly thereafter for clinical examination and pain assessment using Villalta scale (0 to 50). Vitamin D3 levels were estimated after 3 months in all patients.

**Results:** A quarter of the patients had venous ulcers. The majority of patients were female who invariably presented with vitamin D deficiency at the time of enrollment. Patients also presented with other chronic diseases such as thyroid disorders and type 2 DM. All treated patients presented CEAP 5-6. The pain score at admission ranged between 2 to 46 out of 50 (Villalta score) and average pain score was 25.29 ± 10.43. At day 30, patients with corrected vitamin D3 deficiency demonstrated marked pain relief. There was significant reduction in pain in all patients. The pain score ranged from 0 to 31 with average score of 11.37 ± 8.07. (*p-value* = 0.000). At day 30 two patients had no pain at all. Almost all patients expressed satisfaction with the treatment and resumed normal activities. Vitamin D3 checked at 3 months showed no levels that suggested hypervitaminosis. The levels were within statistical parameters. Patients expressed satisfaction with the treatment and treatment was well-tolerated. Clinicians expressed satisfaction and the patient outcomes were rated as satisfactory.

**Conclusion:** Our findings support the available evidence of increased prevalence of Vitamin D3 deficiency in patients with chronic venous diseases. It also supports supplementation of vitamin D3 for earlier recovery and relief of pain in CVD. There is a very strong relationship between Vitamin D3 deficiency in CVD with refractory pain. Correction of Vitamin D3 deficiency via the parenteral route ensured accelerated D3 correction, healing and recovery in almost all patients and must be included in the treatment protocol for all CVD cases. Hypervitaminosis D



was not observed. The treatment was well-tolerated and patients expressed satisfaction with the treatment.

*References:*

1. Holick MF. High prevalence of vitamin D inadequacy and implications for health. *Mayo Clin Proc.* 2006; 81(3): 353-73. Michael F Holick Vitamin D Treatment Guidelines
2. Grant WB. An estimate of the global reduction in mortality rates through doubling vitamin D levels. *Eur J Clin Nutr.* 2011; 65(9):1016-26.
3. Merlino LA, Curtis J, Mikuls TR, et al.; Iowa Women's Health Study. Vitamin D intake is inversely associated with rheumatoid arthritis. *Arthritis Rheum.* 2004; 50(1):72-7.
4. Mohr SB, Garland CF, Gorham ED, et al. The association between ultraviolet B irradiance, vitamin D status and incidence rates of type 1 diabetes in 51 regions worldwide. *Diabetologia.* 2008; 51:1391-8.
5. Munger KL, Zhang SM, O'Reilly E, et al. Vitamin D intake and incidence of multiple sclerosis. *Neurology.* 2004; 62(1):60-5.
6. Wang TJ, Pencina MJ, Booth SL, et al. Vitamin D deficiency and risk of cardiovascular disease. *Circulation.* 2008; 117(4):503-11.
7. Thomas GN, Hartaigh BO, Bosch JA, et al. Vitamin D levels predicts all-cause and cardiovascular disease mortality in subjects with the metabolic syndrome: the Ludwigshafen Risk and Cardiovascular Health (LURIC) Study. *Diabetes Care.* 2012; 35(5):1158-64.
8. Pittas AG, Lau J, Hu FB, et al. Review: the role of vitamin D and calcium in type 2 diabetes. A systematic review and meta-analysis. *J Clin Endocrinol Metab.* 2007; 92:2017-29.

**DOUBLE BANDAGING WITH FOCAL COMPRESSION ON THE WOUND BED. A COMPRESSION TECHNIQUE WITH BANDAGES FOR HEALING VASCULAR ULCERS, WITH OTHER CARDIOVASCULAR HEALTH BENEFITS**

Carlos Sánchez Fernández de la Vega  
*Gallego Health Service, Sergas, Lugo, Spain*

*Introduction:* This is the clinical experience of more than 150 patients, with a simple technique of compression bandaging, for healing vascular ulcers in lower limbs (for almost 20 years).

*Material:* We only need to use bandages and gauzes, to obtain pressure gradients that improve deficit tissue perfusion in the wound bed.

*Method:* We use two bandages. The first one is used for making the focal compression of the wound bed and the second bandage covers the first, to achieve a gradual external compression from the toes to the knee, each turn of the band covers the preceding tour by 50-70%.

Diagnostic tools are: A/ Hand held Doppler ultrasound device. B/ 5.07 Monofilament and 128 Hz tuning fork. C/ Scales. D/ The Edinburgh claudication questionnaire. E/ Camera.

Before applying this technique it is necessary: A/ To make a differential diagnosis. B/ To establish a clinical diagnosis. C/ To measure the Ankle Brachial Index to exclude severe arterial disease.

*Results:* We managed to heal the ulcers, but we have also observed other relevant effects, such as:

1. Early treatment is essential for healing venous leg ulcers.
2. Only mechanical debridement is necessary. Local compression over the wound bed provokes an autolytic debridement by the effect of the arteriogenesis and angiogenesis.
- 3.- We have observed contamination of wound bed, but not infection. Only oral antibiotics are used, if there are signs of infection, such as fever and cellulitis. Local pressure on the wound bed avoids using any kind of antimicrobial agents.
4. Compression is strongly contraindicated in the event of severe peripheral arterial disease, but in expert hands and according to signs and symptoms, making a daily follow-up, it is possible and convenient to apply compression therapy.
5. We have to be patient, the ulcer may take months, even years, to fully heal.
6. New ulcers may appear even on another part of the same leg being treated.
7. No recurrences have been observed on the treated area.
8. Several patients with cardiac failure (excluding grade IV) were treated by compression therapy to reduce edema in legs, and we note an improvement in their quality of life. This can be the logical explanation: Compression therapy in the legs leads to an increase in cardiac preload and a stress on the cardiac chambers, which stimulates a physiological secretion of natriuretic peptides.

We show the most relevant cases.

*Conclusions:* This is an efficient and effective technique for healing vascular ulcers, with other health benefits in these patients.

**“DOUBLE FOCAL COMPRESSION BANDAGING” IN PATIENT WITH CARDIAC FAILURE CAN WE USE COMPRESSION THERAPY IN PATIENTS WITH CARDIAC FAILURE?**

Carlos Sánchez Fernández de la Vega  
*Gallego Health Service, Sergas, Lugo, Spain*

*Introduction:* Cardiac failure is usually listed as a contraindication for compression therapy, due to the increase in preload caused by the displacement of blood volume to the heart. A potential influence of compression therapy on



cardiac function has rarely been studied. Can we use it, in patients with NYAH class I, II, or III heart failure? Of course, in patients with NYAH class IV, compression in the legs is contraindicated: "Patients with cardiac disease resulting in the inability to carry on any physical activity without discomfort. Symptoms of heart failure or anginal syndrome may be present even at rest. If any physical activity is undertaken, discomfort is increased" (NYAH classification).

*Aim:* We have been using compression therapy for years as the only treatment in patients with vascular legs ulcers. Some of them with heart disease, and one of my fears was that compression could worsen their symptoms. For this reason, they were subject to a special follow-up in order to detect signs and symptoms of cardiac decompensation. However, what I observed was that they improved regarding cardiac function and quality of life. There are some papers about this clinical fact. We need to find an explanation for this improvement.

*Method /Technique:* We can reduce oedema and heal ulcers in a patient with occlusive arterial disease, using a simple technique of compression therapy, which we call "Double focal compression bandaging". We also can reduce oedema in a patient with cardiac failure, in grade I, II and probably III NYHA functional classification, making a daily follow-up. Our technique of compression consists of using two bandages. The first bandage is used for the focal compression of the wound bed and another bandage covers the first, to achieve a gradual external compression from the toes to the knee, each turn of the band covers the preceding one by 50-70%. The area of the ulcer receives the pressure of 3 layers (that of the pressure over the wound bed, and the double effect of the external gradual compression) Fig 1.

*Material and Diagnostic tools:* 1. We use gauzes to make a padding 1 cm thick of, in size similar to that of the ulcer, surpassing its edges. This is what we call focal compression. 2. Adhesive bandage for fixing the padding to the wound bed. 3. Strong inelastic compression bandaging (10x12cm) to make the gradual external compression. 4. Physiological saline solution for cleaning the wound bed. 5. Adhesive tape for fixing the bandages and scissors to trim the gauze used as focal compression.

*Diagnostic tools:* A/ Hand-held Doppler ultrasound device. B/ 5.07 Monofilament and 128 Hz tuning fork. C/ Scales. D/ The Edinburgh claudication questionnaire. E/ Camera: We take photos of the wound bed at the beginning of treatment, and whenever the bandage is removed, this way, we can observe the clinical course of the ulcer until it heals. F/ Chest Radiology.

Double focal compression bandage technique is a compressive therapy modality which consists of focusing the pressure on the wound bed to generate pressure gradients, using only gauzes and bandages, which facilitate revascularization in this area, evidenced by an increase in granulation tissue, which leads to the healing of the ulcer. More

than 150 patients were treated using this technique with positive results (Fig 3 shows an example). This technique of compression achieves sub-bandage pressure peaks in order to increase blood flow by the effect of the muscle pump. We can measure local pressure by Picopress®. Hugo Patsch has shown the advantages of inelastic bandages over elastic bandages, since they exert a greater pressure when exercising and a lower pressure at rest, so they behave in a more physiological way and are better tolerated. His concept of Static Stiffness Index is fundamental in understanding the physiological effect of bandages on the calf muscle pump. We have to consider the following concepts:

A / Working pressure: This is the pressure exerted by the compression bandage when the patient exercises.

B / Resting pressure: The pressure exerted by the compression bandage when the patient is at rest.

C / Static Stiffness Index: We quantify it by the pressure difference between the pressure exerted by the bandage at rest and that exerted while standing. As a rule of thumb regarding material used, inelasticity is defined as an increase greater than 10 mm Hg of pressure, when going from resting to standing, whereas if it is less than 10 mm Hg we speak of elasticity.

Static Stiffness Index (SSI) for elastic material without pad over the wound bed is 9. If we apply a 1 cm pad, SSI is 35. We found sub-bandage pressure peaks (1 cm padding) over the wound bed of more than 95 mmHg while walking (inelastic bandaging has better physiological effects on the calf muscle pump).

*Results:* More than 150 patients were treated using only this technique, with a positive results. Many of them were treated before with different therapies with negative results. We present our experience in two patients with cardiac failure (NYHA II-III) that were treated by this technique (images and radiographic comments). When I started treating these patients with compression to reduce oedema, my fear was that compression could increase the cardiac preload and decompensate heart failure. For this reason, we carried out a daily following in these patients. Two clinical cases of leg ulcers and cardiac failure were treated with this technique are presented:

*Case report 1:* Female 86 years old, with the following background diseases: Arterial hypertension, type 2 diabetes mellitus, dyslipidaemia, and severe obesity. She takes oral anticoagulants because of chronic atrial fibrillation (CAF). On July 2012, she was admitted to hospital because of rectal bleeding and severe anemia. She was diagnosed of colonic diverticulosis. In November 2013 the patient suffered a new rectal hemorrhage, and again was sent to hospital. This time, and after consulting cardiologists, it was decided to terminate anticoagulation. The patient was discharged from hospital one week later. One month later, the patient suffered a trauma on her leg, and we applied the compression therapy "Double focal compression bandaging", making a daily follow-up of the ulcer's clinical course. We advised her relatives to bandage the leg. Since this date (4-12-2012)



her relatives have bandaged her leg every day, removing it at bedtime and putting it on again in the morning, when she gets up. The patient went in July 2016 to cardiology and this is the cardiac report: Hypertensive heart disease with left ventricular ejection fraction preserved. Chronic atrial fibrillation (anticoagulant drugs contraindicated). Moderate-severe mitral regurgitation. Moderate tricuspid regurgitation. Pulmonary hypertension. Cardiac heart failure secondary to these pathologies. The patient did not have any hospital admission for acute decompensated heart failure. In all this time, we did not modify her treatment and only added a compression bandaging. She died in 2018 after falling down the stairs. She was 91 years old.

*Case report 2:* Female 88 years old. On September 2011, she was admitted to hospital because of a cardiovascular syncope and heart failure. This was due to rapid atrial fibrillation. Background diseases: arterial hypertension, hyperthyroidism, moderate aortic and mitral stenosis. This patient was diagnosed with pretibial vascular ulcer in her right leg with bad evolution, the ulcer did not heal. I started treating the patient with “Double focal compression bandaging technique”, making a daily follow-up, in the beginning, due to the diseases of the patient. We had to be cautious concerning any signs and symptoms of heart failure. One month later a second ulcer appeared close to the first one and three months later, other ulcers appeared in the same leg. Eight months later the ulcer in the right leg had healed, but a new ulcer had appeared on left leg (06-08-2012), eight months later after starting compression therapy. We note that these new ulcers on left leg has very similar form and localitazion (pretibial) to the healed right leg. We applied the same treatment and got the same result: “Ulcer healing”. The ulcers needed several years to heal, and we did a continuous follow-up of the patient. We managed to reduce oedama in her legs, and she had no hospital admissions in these years. There was no modification of her treatment for cardiopathy, we only added “Double focal compression bandaging”. Finally, she died when she was 97 years, not because of heart failure.

*Conclusions:* These two cases in elderly patients with heart disease and vascular ulcers in their legs were healed with compression therapy, a therapy measure that could be contraindicated because cardiomegaly was detected in both cases. For this reason, we continuously monitored the clinical course of the ulcers until they healing, to detect early any sign and symptom of decompensation of heart failure. Both patients continued taking their medications for heart failure. There was no change in their treatments, we only added compression therapy. There was no hospital admission for decompensated heart failure, in either case. They did not die from complications of heart failure and improved their quality of life.

There is a fear of applying compression in patients diagnosed with heart failure. This is due to compression in legs increasing cardiac preload by displacement of blood from the legs towards to heart. This is a truth fact, for this

reason we can not apply compression in patients with heart failure grade IV, but according to this clinical experience, it is possible to do so it in patients with a lower grade of heart failure (I/II/III). We only have to carry out a continuous follow-up of the patient to detect descompensated heart failure.

In my opinion, the improvement of the quality of life in these patients could be explained thus: natriuretic peptides have diuretic, natriuretic and antihypertensive effects. Compression therapy in the legs leads to an increase in cardiac preload and a stress to the cardiac chambers which stimulates a physiological secretion of natriuretic peptides. More studies are necessary for establishing an investigative approach in this sense.

### INFLUENCE OF LEG COMPRESSION TREATMENT ON CARDIAC FUNCTION

Gyöző Szolnoky<sup>1</sup>, Lajos Kemény<sup>1</sup>,  
Imre Bihari<sup>2</sup>, Attila Nemes<sup>3</sup>

<sup>1</sup>*Department of Dermatology and Allergology, University of Szeged, Szeged, Hungary*

<sup>2</sup>*Vein Center, Budapest, Hungary*

<sup>3</sup>*2nd Department of Medicine and Cardiology Centre, University of Szeged*

*Introduction:* The effects of graduated medical compression stockings (MCS) on cardiovascular responses are poorly investigated.

*Methods:* Our multidisciplinary research group undertook investigations in groups of healthy volunteers, secondary leg lymphedema and leg lipedema patients.

In the first group we studied whether the application of below-knee leg MCSs with different pressures (ccl 1 (18-21 mm Hg), 2 (23-32 mm Hg) and 3 (34-46 mm Hg)) could influence aortic pulse wave velocity (PWV) as the gold standard for aortic stiffness measurement evaluated by arteriography.

In the second and third groups we aimed to assess the effects of customized graduated flat-knitted ccl 2 panty-hoses on left ventricular (LV) rotational mechanics measured by three-dimensional speckle-tracking echocardiography (3DSTE) in leg lipedema and leg secondary lymphedema patients.

*Results:* The application of low compression MCSs (ccl 1) leads to a significant decrease in PWV indicating a beneficial cardiovascular influence. Lipedema patients' LV basal rotation showed significant reduction, while LV apical rotation showed significant increase with unchanged LV twist after a 60-min use of compression garment while the use of compression garments does not have detrimental effect on LV rotational mechanics in selected secondary leg lymphedema patients.



**CAN WE PREVENT POST-THROMBOTIC SYNDROME USING THE NOACS IN ACUTE VENOUS THROMBOSIS?**

Pier Luigi Antignani, M.D.

*Director, Vascular Center, Nuova Villa Claudia, Rome, Italy*

The aim of this clinical-instrumental observational research is to observe the anticoagulant effect of Rivaroxaban in patients with recent and previous TEV and in particular if NOACs have fibrinolytic effects on new and older thromboses.

We studied two groups of patients:

The first group:

27 subjects, age 50-70 years, with previous popliteal-femoral DVT.

- Complete femoral recanalization and partial popliteal recanalization (30%).
- Normal creatinine clearance and liver function.

The second group:

19 subjects, age 70-85 years, 11 males and 8 females.

- Partial recanalization of popliteal vein (30%)
- Recent femoral re-thrombosis in previous popliteo-femoral DVT (about 3 years ago).
- Normal creatinine clearance and liver function.

The patients followed the AVKs therapy but modified the treatment for no compliance to dicumarols and starts with NOACs (rivaroxaban 15 mg BID for three weeks, then 20 mg per day).

All patients were submitted to clinical and echo duplex evaluations every week for 30 days.

In the first group we observed the complete recanalization of popliteal thrombosis after 30 days.

In the second group we observed the complete recanalization of recent femoral thrombosis after 14 days and the complete recanalization of old popliteal thrombosis after 30 days.

No adverse events were observed.

These results show the fibrinolytic activity of NOACs also in patients with old thrombosis with partial recanalization. This action is useful to reduce postthrombotic syndrome preserving the integrity of valves.

The introduction of non-vitamin K antagonist oral anticoagulants (NOACs) has fundamentally changed clinical practice in the use of oral and parenteral anticoagulation therapy in the treatment of venous thromboembolism.

Some laboratory tools for determining the rate of thrombus formation and fibrinolysis in whole blood and plasma include techniques such as the thrombelastograph (TEG) and an assay performed in a 96-well microtitre plate (MPA). As reported by Y.C. Lau (*J Thromb Thrombolysis* (2016; 42:535–544) the rate of clot dissolution is more rapid in rivaroxaban patients.

The TEG and MPA identify differences in thrombogenesis and fibrinolysis in different NOACs with major action in rivaroxaban patients. Rivaroxaban had the greatest influence of slowing thrombogenesis, giving a result (69% inhibition) close to that of warfarin (65% inhibition).

This result was confirmed in the EINSTEIN PE study (van Es J et al, *J Thromb Haemost* 2013;11:679–685) in which was observed the early clot regression was observed following acute PE (88 % of clot complete of partial resolution after 21 days of treatment).

**TREATMENT OF HIGH-RISK PREGNANCIES WITH TINZAPARIN**

Kiesewetter H.<sup>1</sup>, Hoppe B.<sup>1</sup>, Becker R.<sup>2</sup>, Entezami M.<sup>2</sup>

<sup>1</sup>*Medical Care Center Haemostaseologicum Berlin, Berlin, Germany,*

<sup>2</sup>*Center for Prenatal Diagnostics and Human Genetics Berlin, Berlin, Germany*

*Introduction:* The efficacy of tinzaparin in high-risk pregnancies (abortions, stillbirths, late complications) also in combination with acetylsalicylic acid (ASA) and anti-D was investigated. *Patients and therapy:* The data of 2858 pregnant women aged between 18 and 53 years (height 143-191cm and weight 43-158kg) were analysed. 2244 had early, late abortions or stillbirths in prehistory. Of these, 115 were treated with (Innohep®) in combination with ASA in cases of confirmed APA syndrome (58) or sticky platelets (57) (ASA dose between 50 and 200mg). With 230 frustrating in vitro fertilisations (IVF) or intracytoplasmic sperm injections (ICSI) in the prehistory, tinzaparin was injected once daily 2 days before the next transfer beginning. Of these, 118 also received ASA (ASA dose between 50 and 200mg) if the pregnancy test was positive. 164 injected Anti-D (Rhopylac® 200-800µg) before and after the transfer for rhesus positivity and hyperergic immune status. 384 patients currently had notches or 46 growth retardation. 28 had placental detachments, 26 had pre-eclampsia and 24 had HELLP syndrome in pre-pregnancy. 132 had an old, 33 a fresh leg vein thrombosis or pulmonary embolism, 22 of them an APA syndrome (13 sinus vein thromboses, 3 brain insults, 1 heart attack, 1 arterial occlusion in history). Of the 155 patients with thrombosis or pulmonary embolism, 87 had a high thrombophilic risk. 17 had acute thrombophlebitis. 33 were smokers. Multiple diagnoses are possible! Of these 2858 patients with high-risk pregnancies, 695 inject tinzaparin in a dose of 3,500IE, 340 of 4,500IE, 1382 of 8,000IE, 317 of 10,000IE, 98 of 14,000IE, and 26 of 18,000IE. 120 patients also injected Anti-D (200-800µg) with hyperergic immune system and rhesus positivity. 13 patients also suffered from antithrombin deficiency (activity < 50%). In addition to tinzaparin (7 in therapeutic dose, 6 in semi-therapeutic dose), they received 4,000-8,000 IU of antithrombin (Cybermin®) injected weekly, at the latest from the 8th SSW onwards, in order to adjust the antithrombin activity to over 50%. *The target was the live birth rate. Results:* Of the 2858 pregnant women, 2741 gave birth to a healthy child, of which 7 had pre-eclampsia and 5 had HELLP syndrome. These 12 released per section. 117 patients had



abortions. 220 patients with previously frustrated IVFs or ICSIs became pregnant at the latest after the 3rd transfer, 211 delivered a healthy child, 9 had an early birth. All 384 patients with notches, thromboses, pre-eclampsia or HELLP syndrome had no abortion. 62 patients suffered from a local allergic reaction. A HIT II did not kick. *Conclusion:* Tinzaparin proved to be effective, safe, tolerable and can be used safely during pregnancy.

#### DOAC TREATMENT FOR FRAGILE PATIENTS

Z Pécsvárady

*Flor Ferenc Teaching Hospital, Kistarcsa Hungary*

Direct oral anticoagulants ( DOAC ) have become the first choice of treatment for preventing atrial fibrillation caused stroke ( SPAF ) or the prevention and treatment of deep vein thrombosis and pulmonary embolism. However - as with all treatments – they have some limitations: DOACs for fragile patients is still a challenging issue. Age, altered renal functions, extreme obesity or low weight, other diseases like malignancy can cause difficulties in deciding the best anticoagulant treatment for them.

The knowledge of how to use DOACs compared to old classical treatments (VKA or LMWH) for these patients to improving on a daily basis as there are several multicenter studies analyzing the possibilities and the limitations, which will be discussed in this presentation.

#### MANAGEMENT OF ACUTE GREAT SAPHENOUS VEIN THROMBOSIS INVOLVING SAPHENOFEMORAL JUNCTION DURING PREGNANCY

Sokol Xhepa

*Department of Vascular Surgery*

*University Hospital Centre "Mother Teresa" of Tirana, Albania*

*Aim:* Superficial vein thrombosis may develop during pregnancy, but because the prevalence is very low (0.05-0.1%) it is unclear whether there is any etiological link. However, the problem may be underestimated as the published literature only includes symptomatic patients. The obstetrician becomes involved in this complication and should know that when the thrombus is progressing toward the saphenofemoral junction, the treatment should prevent deep venous thrombosis (DVT) and pulmonary thromboembolism (PE).

*Materials and method:* In the period January 2014 – January 2018, 15 patients with varicose veins during pregnancy, complicated with acute thrombosis of GSV involving saphenofemoral junction, were treated in our department. A retrospective study was performed. The medium age was 26 (20 – 32). For 4 of them it was the first pregnancy, for 7 the second and for 4 others the third pregnancy. 5 (33.3%) of them had this complication in the

second trimester and 10 (66.7%) of them in the third trimester of pregnancy. The diagnosis was assessed with Doppler ultrasound. In all patients the thrombus was at a distance 0 – 5 cm from the saphenofemoral junction.

*Results:* Apart from the introduction of low molecular weight heparin, we performed the surgical treatment in two steps:

1. during pregnancy, under local anaesthesia, the high ligation of the great saphenous vein;

2. 3 - 6 months after delivery, under spinal anaesthesia, we performed the stripping of the great saphenous vein and the avulsion of the varicose veins.

All patients had a normal pregnancy and delivery process, without any thromboembolic complications. Also, the lactation period after the second surgical step was uncomplicated.

*Conclusions:* In these patients the cooperation between obstetricians and vascular surgeons is necessary to avoid DVT and PE. At the moment no randomized comparison of the efficacy of different treatments is available when the thrombus progression in the GSV reaches a distance of 0 – 5 cm from the saphenofemoral junction during pregnancy. Ligation of the junction under local anaesthesia is a safe and less invasive procedure that does not harm the pregnancy.

#### CURRENT PRACTICE OF THROMBOPROPHYLAXIS AFTER VARICOSE VEIN SURGERY IN HUNGARY

Gábor Menyhei, Szaniszló Jávör

*Department of Vascular Surgery*

*University of Pécs, Hungary*

*Background:* Thromboembolic complications are rare following varicose vein surgery, but evidence-based guidelines are lacking for prophylaxis and there are debates about best practice. We conducted a survey among vascular surgeons in Hungary to gain an understanding of current practice.

*Methods:* A questionnaire was sent to all practising vascular surgeons who are members of the Hungarian Society for Angiology and Vascular Surgery. Type of surgery, type and duration of thromboprophylaxis, factors for choosing selective prophylaxis, routine pre- and postprocedural ultrasound imaging and thromboembolic events were questioned.

*Results:* Great variations were observed in the responses to most of the questions among vascular surgeons in Hungary. The single-dose thromboprophylaxis was most commonly used. Among surgeons who claim to know the postoperative thromboembolic events the rate was very low.

*Conclusions:* The current practice of periprocedural thromboprophylaxis shows great variations in Hungary. Further studies are needed in order to obtain high quality evidence for optimal decision-making in thromboprophylaxis following varicose vein procedures.



**ABDOMINAL DEEP VEIN THROMBOSIS PROFILE IN AN INTERNAL MEDICINE DEPARTMENT: ABOUT 87 CASES**

Djama. Mohamed-Lyes, Agabi-Widad, Meddas-Moussa, Brahimi-Fouzia, Bacha-Hayet, Boucelma-Malika  
*Hopital Bachir Mentouri, Kouba, University of Algiers, Algeria*

*Aims:* The aim of our study is to describe its clinical and etiological profile.

*Method:* This is a single-center retrospective study involving 126 patients with DVT enrolled over a period of 18 years (1996-2018) We looked systematically for patients with abdominal DVT. The diagnosis was focused on imaging (venous Doppler ultrasound, CT or MRI). All patients underwent an exhaustive etiological investigation (Symptoms questionnaire, clinical exam, blood test : CBC, protein C, protein S, antithrombin III, Factor V Leiden, APL, ANA, bone marrow aspiration and biopsy, imaging).

*Results:* 87 patients with abdominal DVT were identified, (46 F, 41 M); mean age was 43.7 years ranging from 16 to 82. Portal and hepatic veins were the main locations, respectively in 55 (63.2%) and 27 (31%). The first sign which lead to diagnosis was: abdominal pain in 73.5% of cases, with abdominal distension in 16%, ascites decompensation in 5% and a cholestasis syndrome in 3.5%. The most frequent causes were: myeloproliferative disorders in 14 (16%), congenital thrombophilia in 11 (12.7%), APL syndrome in 9 cases (10%). The other causes were: systemic lupus, Behçet's disease, inflammatory bowel disease, celiac disease, extra membranous glomerulonephritis, locoregional causes (trauma, hepatic, neoplastic and sepsis). The use of oral contraceptives was noted in 3% of patients. Etiology was not identified in 30 %.

*Conclusions:* Abdominal location of DVT is unusual and remains a reason for hospitalization in internal medicine. The most frequent causes are myeloproliferative and APL syndromes. However, the cause remains unknown in the majority of cases.

**DEEP VEIN THROMBOSIS PROFILE IN A DEPARTMENT OF INTERNAL MEDICINE: ABOUT 85 CASES**

Bounzira –Tewfik, Djama-Mohamed Lyes, Brahimi-Fouzia, Lafrad-Wahiba, Bacha-Hayet-Boucelma-Malika  
*Department of Internal medicine, Bachir Mentouri Hospital, Kouba University of Algiers, Algeria*

*Background:* Venous thromboembolism (VTE) is a common and serious condition with a multifactorial pathogenesis. It may be the first manifestation of an underlying pathology that has hitherto been asymptomatic.

*Aims:* Determine the etiological and evolutionary profile of deep vein thrombosis (DVT) in our department.

*Methods:* Single-center retrospective study involving 85 patients with DVT over a 15-year period from 2004 to 2018.

*Results:* There were 33 men and 52 women, with a mean age of 44 years. The most common reached location of DVT was the lower limbs (45 cases). An unusual location was found in 40 cases divided as follows: the internal jugular vein (2 cases), the cerebral vein (7 cases), the superior vena cava (1 case), the portal vein (17 cases), the superior mesenteric vein (6 cases), the ovarian vein (2 cases) and other multiple locations (5 cases). The risk factors for VTE were as follows: obesity (8 cases), prolonged bed rest (12 cases), recent surgery (4 cases), history of VTE (12 cases), taking combined oral contraceptive pill (11 cases), postpartum (1 case), decompensated heart failure (2 cases) and stroke (4 cases). Radiological confirmation was provided by venous Doppler (54 cases), abdominal ultrasonography (9 cases) and brain angio-MRI (3 cases). The etiological investigation revealed constitutional thrombophilia (9 cases), and acquired thrombophilia (5 cases). Vasculitis and / or connective tissue diseases were found in 9 cases. A neoplastic cause was diagnosed in 12 cases. Almost all patients received anticoagulant therapy. The evolution was favorable in the majority of cases. A recurrence of thrombosis was noted in 1 patient. The occurrence of pulmonary embolism complicating DVT was observed in 12 cases.

*Conclusions:* Despite advances in antithrombotic prophylaxis, DVT remains a major cause of morbidity and mortality of various etiologies requiring a rapid anti-coagulation and especially a careful etiological investigation.

**COLLAPSIBILITY OF THE INTERNAL JUGULAR VEINS IN THE LATERAL DECUBITUS BODY POSITION: A POTENTIAL PROTECTIVE ROLE OF THE CEREBRAL VENOUS OUTFLOW AGAINST NEURODEGENERATION**

Marian Simka, Joanna Czaja  
*Department of Anatomy, University of Opole, Opole, Poland*

Recent research has revealed that patients with neurodegenerative disease sleep longer in the supine position, while healthy controls prefer sleeping in the lateral decubitus position. Thus sleeping in the lateral position may be protective against neurodegeneration. It has been suggested that perhaps the protective role of this body position is associated with better cerebral venous drainage in this body position, which results in more active glymphatic system of the brain (the system responsible for clearance from the cerebral tissue waste products, e.g. amyloid-β).

Since no published evidence exists regarding venous outflow from the cranial cavity in the lateral decubitus



position, we performed a pilot sonographic study of the internal jugular veins in 3 young healthy volunteers and 2 patients presenting with abnormal jugular valves. In all healthy volunteers both internal jugular veins were opened in the supine position and collapsed in the sitting one. In the right lateral decubitus position the right internal jugular vein was opened, while the left one was partially collapsed; and—vice versa—in the left lateral decubitus position the right internal jugular vein was partially collapsed and the left one opened. In patients with abnormal jugular valves both internal jugular veins were opened in both lateral decubitus body positions.

We hypothesize that in the lateral decubitus body position, because of a decreased flow resistance in the extracranial veins, cerebral venous outflow is optimal, which in turn optimizes the activity of the glymphatic system. Therefore, people intuitively prefer this body position during sleep, while other positions are associated with a higher risk of neurodegenerative disorders. Yet, it should be emphasized that our results need to be interpreted with caution, since only a few individuals have been assessed and this discovery should be confirmed in more patients and healthy controls, and by precise quantitative measurements.

**GLYMPHATIC SYSTEMS OF  
THE BRAIN – PHYSIOLOGY AND POSSIBLE  
ROLE OF THIS SYSTEM  
IN NEURODEGENERATION**

Marian Simka

*Department of Anatomy, University of Opole,  
Opole, Poland*

It has long been believed that the central nervous system is characterised by a lack of lymphatic system and that the role of lymphatic system in the brain is played by cerebrospinal fluid. This paradigm has been recently challenged by the discovery of unique system built by astrocytes. This system, called the glymphatic system, is responsible for removal of waste products from the brain. The discovery of the glymphatic system of the brain was inspired by an observation that cerebrospinal fluid fluxes into the brain parenchyma along the perivascular spaces (Virchow-Robin spaces) surrounding the penetrating cerebral arteries. Further research has revealed that water from the periarterial space is actively transported to the interstitial space through aquaporin-4 water channels. Then interstitial fluid is cleared through aquaporin-4 water channels to the perivascular spaces surrounding cerebral veins. In the context of this discovery it is likely that our understanding of neuroimmune and neurodegenerative disorders (such as: multiple sclerosis, Parkinson's and Alzheimer's diseases), and also of traumatic brain injury and some forms of cerebral edema, may need reassessment, since the newly discovered glymphatic system may play a substantial role

here. Interestingly, the glymphatic system is mostly active during sleep, and its activity is higher in the lateral decubitus position in comparison with other body positions. Since it is likely that the activity of the glymphatic system could be impaired in cases of abnormal cerebral venous drainage, this may shed new light at clinical meaning of the so-called chronic cerebrospinal venous insufficiency.

**CEREBRO-SPINAL VENOUS INSUFFICIENCY  
(CSVI) AND ITS POSSIBLE CONSEQUENCES.**

Franz Schelling

(Not only) in cerebrum and spine, venous insufficiencies have two radically different kinds of effects, depending on their either active or passive nature.

There is poor drainage capacity, manifest in reduced vessel calibers, transient or persistent lumen narrowings. Its consequence is sluggish blood pooling in the vascular periphery, which may worsen until arterial inflow pressures are reached.

There are, on the other hand, energetic flow inversions (“reflux”), pressure propagations into the vascular periphery, whose explosiveness, momentum, and peripheral impact intensity knows no bounds.

Whatever impacts on veins from inside and outside the body comes into play here.

Comparing the forces that burden venous pathways overloaded with circulating blood with those impacting on some venous periphery during central vein compressions not vented in the direction of the heart is pathogenetically revealing.

The abundance of evidence on the effects of hindrances to the cerebral blood circulation contrasts with the stunning scarcity if not the absence of corresponding findings made in the spinal cord and spine respectively.

The effects of abrupt central venous blood displacements in the direction of some cerebral and spinal venous periphery, finally, seem often to have been observed. As a rule, however, the active nature of the underlying venous insufficiency might not have been realized.

The most striking of these observations, relating to unresolved questions of CCSVI research, shall be focused upon concretely.

**VENOUS-LYMPHATIC MALFORMATIONS  
AND TREATMENT WITH FOAM  
SCLEROTHERAPY**

Pier Luigi Antignani

*Vascular Center, Nuova Villa Claudia, Rome, Italy*

Treatment by sclerotherapy has been suggested as a first-line treatment of low-flow vascular malformations. This study reports our experience in treating low flow vascular malformations by ultrasound-guided sclerosis with





polidocanol foam at the Vascular Center of Nuova Villa Claudia Clinic in Rome, Italy.

*Materials and methods:* between January 2018 and December 2018, a total of 67 patients were treated (12 children with age lower than 4 years):39 venous malformations in different localities, 8 KTSs and 20 venous-lymphatic malformations and treated by ultrasound-guided foam sclerotherapy. The concentrations of polidocanol used ranged from 0.25% to 3%. The average number of sessions was 4.8 (1 to 16).

All vascular malformations were classified according to the Hamburg Classification. The sclerosing agent was polidocanol used as foam according to Tessari method.

The indication for ultrasound-guided sclerosis and the therapeutic strategy were validated by the multidisciplinary team which includes vascular physicians, dermatologists, vascular surgeons, maxillofacial surgeons and vascular radiologists. A strategy of combined treatment (sclerotherapy and surgery) could be proposed, with the sclerotherapy being performed first to reduce the invasiveness of surgery.

The pre-therapeutic evaluation was primarily clinical to clarify the symptoms (pain, neurological signs and trophic disorder) and the type and size of the malformation(s).

Photographs were taken. Duplex ultrasonography was routinely performed, often supplemented with an angiographic resonance imaging (MRI) or computed tomography (CT) angiography. Clear information about the ultrasound-guided sclerosis treatment was given to the patient and/or parents of juvenile patients.

At the beginning of each treatment session, a pre-treatment echo-Doppler was carried out to verify the type, depth and accessibility of the malformation and to choose the most suitable injection method.

The volume of foam injected was estimated by the amount necessary to obtain a venous spasm, but never exceeded 10 ml. Compression by superimposing an elastic band or elastic tape was applied immediately after treatment and maintained for 3 days when the topography permitted. After this, when the malformation was on a limb, an elastic compression stocking (20-25 mmHg) was worn during the day for 15 days.

A clinical and ultrasound examination was performed on day 8. In cases of repeated procedures, an interval of at least 4-6 weeks between sessions was observed. The decision to continue the treatment or not was made with the patient on the basis of clinical efficacy. At the end of the treatment, patients were followed up in a no standardised manner, usually 1-3 months after the last session.

*Results:* After a median follow-up at 6 months after the last session, 62 out of 67 patients reported a decrease in pain and over 50 % reduction in size was observed.

In the other 5 cases a reduction of less than 50% of the original size was obtained. No collateral effects were reported.

**REASONS OF VENOUS REFLUX MAPPING  
INACCURACIES MISLEADING TREATMENT  
PLANNINGS IN THE US AND  
HOW IT CAN BE IMPROVED**

Khalil Fattahi

*Vein Specialty Medical Clinic, Inc. Campbell, California*

The presenter, based on his 27 years of individual observation and experience practicing focused phlebology in California has implemented a workable strategy and documentation method which guides stepwise approach to treatment planning in cases of symptomatic lower extremity venous reflux disease. Facing the dilemma that in the US almost all venous reflux mappings are performed by RVTs (Registered Sonography/Vascular Technicians) and not by the treating physicians, and the fact that training curriculum of RVTs in the US lacks coverage of proper venous reflux detection and mapping in cases of varicose veins, Dr. Fattahi implemented a change to this common but wrong approach. Surprisingly, in the US most RVTs perform venous reflux mapping with the patient in supine position, or at best with the patient in semi-sitting position! The lack of venous reflux training in RVT curriculum in the US, as admitted by most RVTs interviewed by Dr. Fattahi, became very evident when looking at nearly 1000 ultrasound study reports obtained by DR. Fattahi in the last two decades, in which there was never a report of even a single incompetent perforating vein, while repeat study by Dr. Fattahi in many of these cases revealed clinically important perforating veins reflux in many which changed the outcome of the treatments for the better. Dr. Fattahi will present his styles of documenting venous reflux in a fashion that outlines treatment steps.

**FOAM-WASHOUT SCLEROTHERAPY,  
A TECHNIQUE GEARED TOWARD REDUCING  
SHORT & LONG-TERM COMPLICATIONS  
OF REGULAR FOAM SCLEROTHERAPY,  
AND COMPARISON WITH EXISTING FOAM  
SCLEROTHERAPY METHOD**

Khalil Fattahi

*Vein Specialty Medical Clinic, Inc. Campbell, California*

Foam sclerotherapy (FS) has proven itself to be a valuable treatment modality for small and large varicose veins (VV) of the lower extremities. However, it is associated with a number of complications such as vision disturbances, transient neurological deficits, migraines, deep vein thrombosis (DVT), & superficial phlebitis. The author developed Foam Washout Sclerotherapy (FWS) to remove all or most of the injected foam from the targeted varicosity within seconds after the foam comes in full contact with the endothelium of the targeted vein, and optimal damage to the endothelium was attained. In FWS the treating physician has control over duration of foam



contact with the endothelium. The active application of negative pressure at the site of removal of foam prevents it from entering the deep veins via perforating veins and guides the flow of foam in the desired direction within the varicosity. 727 subjects were selected, of which 612 completed the study having 852 cases of greater (GSV) and short saphenous (SSV) and antero-lateral tributary (ALT) varicosities. Cases were randomly selected to receive either the current popular foam sclerotherapy or foam-washout sclerotherapy over a 6-month period. Patients were evaluated for short & long-term complications by phone interview in 24 hours, followed by in-office visits including ultrasound & Doppler studies in 2 weeks and then at 2 - 6 months.

*Results:* Treatment efficacy, judged by occlusion of varicosity, was similar in both groups. However, the combined short and long-term complications were less than 2% in foam-washout group as compared to near 20% in regular foam sclerotherapy group. In patients who experienced both treatment methods, patient satisfaction was much higher in the foam-washout group related to no pain during the injection and lower frequency and intensity of problems related to trapped blood (superficial phlebitis).

*Conclusion:* Foam-washout sclerotherapy is a modification of Foam Sclerotherapy technique, with a few advantages, that can be performed and mastered by physicians experienced in foam sclerotherapy. While it provides results similar to the current foam sclerotherapy method, its level of patient satisfaction and significantly lower rate of complications make it a preferred method of foam sclerotherapy of varicosities, where technically it can be applied.

#### **DIAGNOSIS AND TREATMENT OF A 27 CM LONG SYMPTOMATIC INCOMPETENT PERFORATING VEIN AT THIGH LEVEL. CASE PRESENTATION**

Khalil Fattahi

*Vein Specialty Medical Clinic, Inc. Campbell, California*

A 43 year old female presented with right superficial varicosities and progressive leg discomfort including severe pain and burning in medial aspects of right thigh for 4 years when standing. Doppler & duplex US revealed severe reflux in a 27 cm long tortuous perforating vein (running below the deep fascia) arising from femoral vein at 3 cm distal to the SFJ and continuing sub-fascia very close to the femoral vein all the way to near knee level where reflux created superficial post-medial knee and calf varicosities.

Dr. Fattahi will demonstrate findings in this case and the treatment plan that selected and executed, resulting in satisfactory ablation of this extended thigh level incompetent perforating vein.

#### **MEDICAL GRADE PLASTIC CONTAINERS FOR OXYGEN AND CARBON DIOXIDE TO CREATE SCLEROSING FOAM**

Alfonso Cardenas

*Purpose:* The possibility of containing a mixture of oxygen and CO<sub>2</sub> (30-70%) in IV solution bags, and plastic syringes was analysed, all were sterile medical grade, as well as the non-flammability of a such mixture.

*Materials and methods:*

- 50 bags for 1000 cc of IV solution were previously emptied of their pre-existing physiological solution
- 25 needles caliber 20 to 22, as well as the same amount of 3-way stopcock, all of random, new, and sterile brands were used to contain the gas mixture within the bags, with the needle inserted in the valve and the 3-way stopcock in the closed position for containing gases.
- 25 syringes of 10 cc
- 25 new and sterile 3 way stopcocks

Containment tests were made at atmospheric and forced pressure of 200 mm / Hg under immersion, as well as the subsequent generation of foam with Polidocanol 7 days later. The flammability of the gas mixture was also verified, with flame and sparks, resulting in a non-flammable effect.

*Results:* Loss of volume: Negative. Passive Immersion: Lossless. Immersion at least 200 mm / Hg pressure: Lossless. I.V. Bags: No noticeable failure was detected using the bags, needles or 3-way stopcocks. Syringes: No noticeable failure was detected. At the end of each week, foam with Polidocanol with the Tessari method was generated, no variation was detected. (Compared with recently obtained gases). Flame and sparks test: They were not able to generate flame at the CO<sub>2</sub>/Oxygen outlet.

*Conclusion:* It is safe to transport or contain both oxygen and carbon dioxide concentrations in different plastic bags and syringes for at least 7 days (and preparing foam after that period). Bags tolerate a gas pressure of 200 to 300 mm Hg without showing any sign of leakage. Syringes tolerate external high pressure when they are connected to a 3-way stopcock in the closed position. This study can also conclude that no explosive hazards exist with the mixture 30/70% of Oxygen and Carbon Dioxide.

#### **DOES THE EXTENSIVE ENDOVENOUS SURGERY ACCELERATE VENOUS ULCER HEALING ?**

Žernovický F Jr, Osuský M, Machajová L,  
Tomka J, Žernovická K\*

*Department of vascular surgery NÚSCH Bratislava, Slovakia*  
*\*ANGIO Bratislava, Slovakia*

Common cause of venous leg ulcers is the ambulatory venous hypertension. A venous pressure above 45 mm Hg increases the probability of development of an ulcer. The higher the ambulatory venous pressure, the higher is



the risk of the venous ulceration. The venous hypertension is the result of obstruction, reflux or combination of both. The aim of therapy has to be the reduction of venous hypertension. Standard techniques for treatment of venous hypertension (cross-section, stripping, endovenous ablation, SEPS, sclerotherapy) did not significantly influence the time of defect healing. However, our experience with augmented endovenous surgery and rational medication, expressly abbreviate the healing time, number of additional ambulatory sessions as well as patients pain and comfort. Aim of our approach is combination of two techniques, endovenous thermal or non thermal ablation of truncal vein reflux with terminal interruption of reflux sources (TIRS) in one session. TIRS is a technique for super-selective obliteration of terminal reflux sources in the ulcer region. The philosophy of this technique is based upon translumbar ultrasonography, where multiple dilated venous plexuses are observed, often with an extensive reflux. Therefore, the elimination of these sources of local venous hypertension is essential for the healing of the ulcer. Selective obliteration of terminal reflux sources by means of ultrasound guided foam sclerotherapy effectively eliminates local venous hypertension and accelerates the healing. For filling up the infra-ulcerous venous plexuses, we successfully use RFA catheter or even better MOCA catheter, what's more comfortable and less painful.

*In contradiction with* frequently quoted studies in this field, our experience strongly support that the extensive surgical approach "from top of the reflux to the terminal reflux sources below the leg ulcer" (in one session) with support of inelastic compression and rational medication accelerate the healing of the venous leg ulcer.

**THE NEW N-BUTYL-2-CYANOACRYLATE  
GLUE ABLATION CATHETER  
INCORPORATED WITH APPLICATION  
GUIDING LIGHT FOR THE TREATMENT  
OF VENOUS INSUFFICIENCY:  
TWELVE-MONTH RESULTS**

Kürzat Bozkurt

*Istanbul University Faculty of Medicine, Turkey*

*Aim:* To present the early results of a retrospective study of the use of novel n-butyl-2-cyanoacrylate based non-tumescent endovenous ablation with a guiding light for the treatment of patients with varicose veins.

*Methods:* Five hundred and thirty-eight (C2-C4b) patients with great saphenous vein incompetency underwent n-butyl-2-cyanoacrylate ablation. No compression stockings were used after the procedure. Duplex ultrasound imaging and clinical follow-up were performed at 6th month, and 12th month. Clinical, etiological, anatomical, pathophysiological classification; venous clinical severity score; and completed Aberdeen varicose vein questionnaire were recorded.

*Results:* The mean ablation length was  $25.69 \pm 4.8$  cm, and the average amount of n-butyl-2-cyanoacrylate delivered was  $0.87 \pm 0.15$  ml. The mean procedure time was  $11.7 \pm 4.9$  min. Procedural success was 100%, and complete occlusion was observed after treatment and at the third-day follow-up. We observed ecchymosis in five patients (1.00%) at the entry site at the third-day follow-up. Phlebitis was encountered in six (1.20%) patients. No skin pigmentation, hematoma, paresthesia, deep vein thrombosis, or pulmonary embolism was observed. Kaplan-Meier analysis yielded an occlusion rate of 99.4% at the 12-month follow-up. All patients had significant improvement in venous clinical severity score and Aberdeen varicose vein questionnaire scores postoperatively ( $p < 0.0001$ ). Venous clinical severity scores decreased from  $5.43 \pm 0.87$  to  $0.6 \pm 0.75$ . Aberdeen varicose vein questionnaire scores decreased from  $18.32 \pm 5.24$  to  $4.61 \pm 1.42$ .

*Conclusions:* The procedure appears to be feasible, safe, and efficient in treating the great majority of incompetent great saphenous veins.

**USAGE OF AMERICAN AND TURKISH GLUE  
FOR THE TREATMENT OF VARICOSE VEINS**

Imre Bihari, Peter Bihari, George Ayoub

*A+B Clinic, Budapest, Hungary*

*Introduction:* Cyanoacrylate glue has been used in surgery for more than 50 years. Since 2011 it has also been used for varicose vein surgery. Glue surgery has been performed by us since December 2016.

*Aims:* To compare the two different glue types.

*Patients:* Up to now 64 glue interventions were performed for varicose veins. In 13 patients both legs were treated in one session (which means 40,6 % of legs in one session). There were 15 male legs and 49 female legs. Patient age was between 17 and 83, mean 51.2 years. They were GSV in 53 cases, SSV in 4, accessory anterior vein in 2 and perforator vein in 5 cases. The diameter of treated veins was between 4 and 9 mm, mean 5.9 mm.

*Methods:* Two different cyanoacrylate glues were used which required two different methods. One is the American VenaSeal and the other is the Turkish VenaBlock glue. In both cases glue was introduced with Seldinger's catheter technique. VenaSeal is delivered step-by-step and VenaBlock is given fast and continuously. In both cases hand and ultrasound head compression was used. Local anaesthetic was used only at the puncture site. Compression stockings or bandages are not necessary after the intervention.

*Results:* After surgery every saphenous stem and perforator vein was closed and within half an hour all the patients were discharged. The remaining tributaries and reticular veins were treated in another session. In two cases after GSV treatment, accessory anterior vein recurrency was experienced. One of them was treated with glue and the



other with laser. In the SFJ and SPJ the distance between the occlusion in the saphenous vein and the femoral vein was between 0 and 55 mm. In 9 cases (16.6 %) an inflammatory response was experienced along the thigh part of the GSV. In two cases phlebitis developed in a side branch. Painkillers were taken only in the inflammatory cases. Turkish glue bonds very fast and the American slowly. It has some important consequences.

**Conclusions:** In spite of the small number of cases, there are some conclusions. Site of attachment at the junction is not predictable. Glue is also suitable for perforator vein occlusion. The two different cyanoacrylate glues required two different methods. Inflammatory response was seen only on the thigh part of the GSV which resolved in some days for conservative treatment. Remaining small varicose veins require a second session for sclerotherapy. Patients were pleased with the intervention and the short-term results. This intervention is the most patient-friendly surgical intervention for varicose veins.

#### COMPARISON OF LASER AND GLUE IN PERFORATOR VEIN TREATMENT

Imre Bihari, Peter Bihari, Szilvia Bokros, Ayoub George  
*A+B Clinic, Budapest, Hungary*

**Introduction:** Having introduced laser crossectomy 10 years ago, fewer recurrences were found at the SFJ. After following our patients for some years perforator vein recurrences were experienced. This was the reason why we decided to treat insufficient perforator veins during our varicose vein laser operations.

**Patients:** Our patients treated between August 2018 and July 2019 were randomised into two groups: one was the laser and the other the glue group.

**Methods:** For laser occlusion 103-450 J (mean 296 J) was given for perforator treatment. For glue treatment 0.1 – 0.4 ml (mean 0.18 ml) glue was given with direct puncture at the fascia level of the perforator vein.

**Results:** 89 perforator veins were treated with laser, of them 25 (28.0 %) remained open. Of these open perforator veins 17 were refluxive (19.1 %).

68 perforator veins were treated with glue, from them 14 (20.6 %) are open. From these open perforators 9 are refluxive (13.3 %).

As a complication, paresthesia was experienced in laser surgery cases in 61 cases (68.5 %). This was a temporary observation lasting usually for 3 months. There was no inflammatory response in the crural part in glue treated perforator cases. There were no thromboembolic complications. It was difficult to prove it in glue cases, but clinically there were no signs.

**Conclusion:** Conclusion: Regarding the success rate, glue treatment seems better. Regarding complications, glue treatment is also recommended.

#### GLUE TREATMENT OF VARICOSE VEINS

Attila Szabo

*VP-Med Health and Education Centre, Budapest, Hungary*

**Aims:** Using VenaSeal glue ablation makes it possible to painlessly stop the reflux in the insufficient main vein trunks of the lower extremities. In our presentation we provide the 3-year results of more than 500 cases and show our methods for perforator vein glue closure.

**Methods and results:** From June 2016 to January 2019 we treated patients (average age 54 years, average age, 140 men, 258 women) with saphenous reflux and varicosity using VenaSeal glue. The procedures were performed on 569 limbs of 398 patients - 251 GSV, 140 GSV both sides, 12 SSV, 5 SSV both sides, 26 GSV+SSV; 376 patients belonged to CEAP 2-3, 22 patients to CEAP 4-6, only primary varicosities. The mean diameter of the GSV was 6.5 mm. The length of the treated vein segment was 48 cm on average, using 1.44 mls amount of glue per case. Complete occlusion was found in all cases after 1 month at the ultrasound control. Postoperative pain reported by the patients on a visual analogue scale was under 1.2/10, VCSS scores showed significant improvement of the QOL of the patients after 1 month. Postoperative skin reaction was observed in 52 cases, which correlates to literature data.

According to the experiences of some international centres we started the percutaneous closure of perforator veins with VenaSeal glue. Our first results are encouraging, with the 1 month closure rate above 90 percent.

**Conclusion:** VenaSeal glue endovenous ablation is a promising possibility for the treatment of varicose vein with a painless method. There is no need for tumescent anaesthesia, no need for compression stockings and the operated leg can be used immediately. International results show comparable closure rates to tumescent methods.

VenaSeal glue perforator closure is an easy applicable, painless ambulatory method with good closure rates. Perforator glue ablation is also easy to combine with tumescent ablation or foam sclerotherapy.

#### PITFALLS OF WRITING GUIDELINES FOR VASCULAR DISEASES

Gábor Menyhei

*Department of Vascular Surgery University of Pécs, Hungary*

In vascular surgery, the principles of evidence-based medicine have become critical as new technologies evolve. Clinical practice guidelines aim to assist clinicians in decision-making. During the writing process, factors other than evidence should be considered such as patients' preferences and the availability of surgical expertise and resources. Reaching a consensus and providing an accurate synthesis of the literature can be extremely difficult as the literature is sometimes full of contradictory results. One of the most crucial issues of writing guidelines is the length of



the process, as if it is too long some recommendations can become outdated by the time of publishing due to the fast development in the field. As a member of the writing committee of two recent clinical practice guidelines, the author of this presentation aims to summarize the most common problems the writing committee is facing. In the future, it will be necessary to improve the quality of evidence and the usefulness of these guidelines, in order to give greater confidence to vascular surgeons and patients.

The aim of a guideline is to show a reliable basic line of diagnosis and treatment. The aim of such a meeting is to raise the level of this basic line. A lot of presentations heard at this meeting show that new-and-new equipment and results and evidences are coming, but this is the task of these meeting.

### **SMALL SAPHENOUS VEIN REFLUX - HOW TO TREAT IT WISE, NOT TWICE?**

Žernovický F Jr, Machajová L, Dulka T,  
Tomka J, Žernovická K\*

*Department of vascular surgery NÚSCH  
Bratislava, Slovakia*

*\*Angio Centrum, Bratislava, Slovakia*

Published data about small saphenous vein reflux in population point out incidence between 18% and 22%. Generally, we can say that every fifth patient with reflux, could be a candidate for SSV treatment. This field is not the most popular field in venous surgery, despite of that, we should dedicate appropriate attention for these patients. Unrecognized SSV reflux is the most common cause of venous ulceration.

The anatomy of the sapheno-femoral junction is relatively constant, while that of the sapheno-popliteal junction (SPJ) is highly variable. The SSV terminates at the SPJ, which is usually located in the popliteal fossa at the level of the knee crease. However, the ultrasound investigations have revealed great variation in the location of the SPJ in relation to the knee crease. There is also significant variation in the presence and location of the Giacomini vein. We differ tree types of cranial extension of SSV (axial, post-axial, or a combination of both). All this details are important for decision making: when and which technic should be used. Which treatment offers more comfort and better results? When is it adequate to use thermal ablation, when it is better to prefer non-thermal non-tumescent ablation, or for which patient we simply use the duplex guided foam sclerotherapy? Will the nonthermal non-tumescent technics eclipse the radiofrequency or the laser treatment in this field? Last but not least we would like to discuss the economical point of view. Is it scientific to treat these patients just with compression and medication? Is the glue or MOCA despite their price are better because of the more safety and effectivity of the treatment? All these questions will be answered in our presentation, based on experience with more than 700 small saphenous vein treatment in conformity with international guidelines for endovenous treatment.

### **AESTHETICS OF THE LEGS - LATEST AESTHETIC TECHNIQUES, LATEST METHODS IN CHRONIC VENOUS DISEASE MANAGEMENT**

Éva Szabó

*Department of Dermatology, Faculty of Medicine,  
University of Debrecen*

Recently in dermatology and surgery practices aesthetic issues come into views more and more often. Besides the face, neck and decollate, the hand and leg aesthetics are also becoming increasingly important.

For the aesthetic appearance of the legs one has to consider the shape, length, diameter, proportions, equable pigmentation, normal epidermal and dermal thickness, normal amount of collagen and elastic fibers, a smooth skin surface, normal hydration, non-visible veins and tendons, wrinkles and cellulite. Aesthetic and surgical procedures can help to correct the patient's body and improve patients' appearance. The lecture aims to overview some of the effective interventions aiming at improving or restoring skin/leg aesthetics.

Hyperpigmented macules can be successfully treated with Nd:YAG laser or intense pulsed light, whereas collagen production can be stimulated with ablative lasers. The aesthetic treatment of dilated veins is also important. The CEAP C0-C2 stage of chronic venous disease (CVD) mainly presents an aesthetic problem, but the treatment in this stages is nevertheless necessary. Compression stockings and venoactive drugs are suggested. Various skin symptoms appear in chronic venous disease. Skin barrier function is usually impaired and hydration and lipid replacement is necessary. Irritation, eczema can also develop in CVD. In acute inflammation steroid containing creams, then barrier function regeneration with ceramides and moisturizers are recommended. For the treatment of telangiectasias, transcutaneous lasers e.g. Nd: YAG laser is a good option. The minimally invasive methods are also preferred in vein surgery.

In the therapeutic plan of leg aesthetic problems combined treatment often recommended. Individualized treatment focusing on the patient's needs is necessary.

### **HEMODYNAMIC REMODELING OF THE VEIN WALL**

György L. Nádasy<sup>1</sup>, Gabriella Dörnyei<sup>2</sup>,

Anna-Mária Tökés<sup>3</sup>, Bettina Patai<sup>4</sup> and Zoltán Várady<sup>5</sup>

*Physiology Dept<sup>1</sup>, Morphology and Physiology Dept,  
Health Sciences Faculty<sup>2</sup>, Molecular Oncology Research  
Group, 2nd Dept of Pathology<sup>3</sup> Semmelweis University  
Budapest; as well as Military Hospital, Dept of Traumatology,  
Budapest<sup>4</sup> and Venenlinik, Frankfurt a. M. Germany<sup>5</sup>*

In the lecture our present knowledge will be surveyed – partly based on our own studies - proving that the structure of the vein wall is dependent on chronic hemodynamics. The healthy vein wall is relatively thin, however, it can be somewhat thicker at places subjected to higher pressure.



It is distensible and contains a substantial amount of smooth muscle and elastin. The vein axis is straight or only slightly bent. The cross-section of the lumen is cylindrical, while it can be elliptical at low pressures, without local narrowing and dilation. Our own experiments prove that similar to the arteries, the diameter of the lumen of the veins is controlled by the shear stress exerted by the flowing blood on the endothelium. Circumferential force on the wall will determine wall thickness: leg veins have thicker walls than upper body veins of similar diameter, even in normal physiological circumstances. The frequently mentioned large distensibility of the veins is valid for lower pressures only. At higher pressures the vein wall turns rigid and has a substantial resistance against tearings: properties which make them suitable to be used as arterial bypasses in vascular surgery. The amount of elastin in the wall is sometimes surprisingly large: it can be supposed that frequent alterations in pressure stimulate smooth muscle cells to secrete (proto)elastin. Valves are usually located before the confluence of a vein into a larger branch. It would be interesting to study what kind of local factors stimulate their formation at these sites. Blood flow with alternating direction might be one idea. A healthy vein wall can produce a substantial contraction, loss of smooth muscle and elastin, their replacement with fibrotic tissue is characteristic in many pathological situations. The sympathetic neural system plays an essential role in the control of the contractility of the veins in many vascular territories. According to our studies, the amount of sympathetic nerves innervating the leg veins depends on the venous pressure (gravitation). Other works by us have proven that gravitation has an important role in the control of the secretory activity of the venous endothelium too. Chronically decreased gravitation (lengthy bed rest, microgravity during cosmic travel) substantially reduces the effectiveness of orthostatic venous reflexes, inducing serious complications at cessation of the microgravity (mobilization of the patient, return to the Earth). Typically, venous networks do have a substantial amount of collaterals. This makes it possible, that during routine phlebological treatment, we can eradicate the pathologically deformed veins without invoking a serious venous stasis at the same time. If blood flow in a venous branch is chronically elevated, the process of morphological hemodynamic remodeling transiently weakens the passive (elastic membranes) and active (smooth muscle cells) force-bearing elements. Incompetency of perforators can be one reason for the chronically elevated blood flow in the affected superficial branches. Weakened during the process of hemodynamic remodeling, the venous wall will not then be able then to resist the gravitational pressure load and varicosity develops. Our animal experimental studies revealed that this double chronic hemodynamic load (flow plus pressure) could be in the background of leg varicosity disease. (Support, OTKA 32019, OTKA 42670, Dean of the Medical Faculty, Semmelweis University).

### PREVALENCE OF CHRONIC VENOUS DISORDERS OF LOWER LIMBS IN ALGERIA: PRELIMINARY RESULTS

Boucelma Malika<sup>1</sup>, Azzam Mustapha<sup>2</sup>

<sup>1</sup>*Bachir Mentouri Hospital, Kouba University of Algiers, Algeria*

<sup>2</sup>*Imperial College, London*

*Objective:* The aim of this study was to investigate the prevalence of chronic venous disease in a sample of the general population of Algeria.

*Methods:* This cross-sectional epidemiological study interested 11 care centres in Algiers. All patients underwent physical examination and the presence of varicose veins, trophic changes and venous symptoms was recorded.

*Results:* Our sample includes 571 patients (155 men, 416 women). The mean age is (46±16.3) years old. Varicose veins and telangiectases were the most common objective signs in both men and women. Older people were more severely affected. Telangiectases and varicose veins were more frequent in women 50,1% versus 38.1% and 31% versus 23,2% respectively. Varicose veins and pitting oedema increased with body mass index (p<0.01 and p<0.03).

*Conclusion:* Our results show a high prevalence of chronic venous disorders of the lower limbs in the general population of Algeria.

### ENDOVENOUS ABLATION OF LEG VEINS: SHOULD WE BE MORE OR LESS RADICAL?

Alexander Flor

*Vein practice at Private Clinic Döbling, Vienna, Austria*

In phlebology we always discuss if we should use a technique more radical or less radical. We were educated that every patient's Vena Saphena Magna (Parva) needs to be stripped over the whole length with access through big incisions in the groin or in the poplitea. Then came miniphlebectomy in the seventies, scientifically described nowadays in the ASVAL technique, no Crossectomy, no stripping anymore.

Using Endolaser in our clinic since 2001 we realized that one big advantage of the Endolaser is that due to the possibility of multiple punctures one could just treat insufficient vein segments, and spare healthy vein segments. For example: treating less truncal veins in the lower leg, because they are of normal size, no reflux. Or not treating the greater saphenous vein distal of the distal point of insufficiency in Hach 2-3 varicosity, when the insufficient vessel is a vein parallel to the greater saphenous vein yet directly below the skin.

Yet we have to realize that in some patients or in some anatomical situations this concept might end up in a higher rate of recurrency. In the presentation some situations are presented in which a more radical, even prophylactic use of the Endolaser might be advisable.



**PULSATILE VARICOSE VEINS OF THE LOWER LIMBS**

Nadjib Mohamed Bouayed

*Vascular surgery College of Medicine, Oran, Algeria*

A large tricuspid insufficiency or right heart failure can cause large and pulsating varicose veins of the lower limbs. 2 cases will be presented. These are two young male patients. Both had large pulsatile dilatation of the great saphenous veins which were complicated by painful right leg ulcers and swelling. This vein pulsatility was present even when the leg was elevated. One patient had a scar from a right inguinal incision secondary to an attempt by a surgeon to ligate the saphenofemoral junction and who withdrew by noticing the large pulsations of the great saphenous vein's neck thinking that it was an arteriovenous fistula. Indeed, there were no signs of arteriovenous fistula. A patient had an Ebstein disease and the other patient had already had a tricuspid plasty, 3 years earlier. Echocardiography showed a significant persistence of tricuspid leakage. Duplex ultrasound showed an arterial-like pulsating flow in the great saphenous veins, the inferior vena cava and ilio-femoral veins. Both patients were treated with elastic compression and were oriented towards cardiac surgery. Tricuspid regurgitation is a rare etiology of leg ulcer. A review of the literature is reported.

**VISCOSITY ESTIMATES IN CHRONIC VENOUS DISEASES**

Fausto Passariello

*The Vasculab Foundation, Napoli, Italia*

*Introduction:* Viscosity is commonly measured on whole blood in a time consuming and expensive way, using a viscometer. Though several different devices are available for measurements, generally viscometers are not easily found in a clinical environment, thus being viscosity seldom assessed in daily work and confined instead in research settings.

*Methods:* A minimal invasive and simplified estimate of blood viscosity can be achieved from a venous blood sample, measuring hematocrit (%), total serum proteins (g/dL) and plasma fibrinogen concentration (mg/dL) (De Simone). The method is based on a multiple linear regression of viscosity at different shear rates. The computed estimates however are reliable in normotensive patients and are not validated when the input parameters are out of a required range.

Exclusion criteria are: acute inflammatory conditions, tumors, severe comorbidity, pregnancy, recent trauma, wide burns or surgical intervention (< 1 month), ongoing anti-coagulant therapy, emo-transfusion, hemorrhage.

The user can introduce several remarks. For instance, info about (C)EAP for venous insufficiency (CVD), Fontaine's stage for peripheral arterial diseases (PAD), max ulcer diameter for venous leg ulcers (VLUs).

Measurements are recorded using the '.' as decimal separator. The valid range for the total plasma protein concentration (serum proteins+fibrinogen/1000 or TPP) is 5.4-9.5 g/dL. The valid range for the hematocrit is 32-53 %.

*Results:* Viscosity (cP) depends on the value of the shear rate ( $s^{-1}$ ), where the measurement is performed. The resulting shear stress ( $dyne\ cm^{-2}$ ) depends also on the yield stress (TY), which has the same dimensions as the shear stress.

Our sample (44 cases) was constituted by a valuable number of cases of venous insufficiency and venous superficial or deep thrombosis, whilst just a small number of cases of lymphedema and other unspecified vascular diseases was available. Venous insufficiency got the highest TY and HS value and venous thrombosis the smallest ones. Other diseases are characterized by intermediate values.

Average Viscosity and Pathology											
#cases	Pathology	HCT	TPP	TY	VLS	LS	LMS	MS	LHS	HS	
22	venous insufficiency	42.6	7.53	0.0195	78.71	30.36	10.00	5.02	4.41	4.32	
11	venous superficial or deep thrombosis	37.8	7.46	0.0148	61.50	21.12	7.77	4.34	3.83	3.74	
1	venous ulcer	38.7	7.80	0.0142	66.77	24.07	8.39	4.53	4.00	3.90	
1	peripheral arterial disease	43.9	7.20	0.0207	81.29	31.62	10.41	5.13	4.51	4.42	
4	lymphedema	39.3	7.33	0.0159	65.94	23.45	8.38	4.52	3.98	3.89	
5	other vascular diseases	41.3	7.30	0.0176	72.62	27.02	9.26	4.78	4.21	4.12	

*HCT – Hematocrit (%), TPP – total plasma proteins (g/dL), TY – yield stress ( $dyne\ cm^{-2}$ ), VLS - viscosity at very low shear rate ( $0.1\ s^{-1}$ ), LS - viscosity at low shear rate ( $0.5\ s^{-1}$ ), LMS - viscosity at low medium shear rate ( $5.2\ s^{-1}$ ), MS - viscosity at high medium shear rate ( $52\ s^{-1}$ ), LHS - viscosity at low high shear rate ( $104\ s^{-1}$ ), HS - viscosity at very high shear rate ( $208\ s^{-1}$ ).*

*Conclusions:* The simplified viscosity data collection protocol implemented in the current work can quickly collect values in a population of much greater numerosness. It takes into account viscosity in the daily management of patients as well as in the pathophysiologic reasoning on their diseases. Estimates of course can provide inaccurate values and depend strongly on the range of input parameters. In addition, they can be computed just in selected classes of patients. The current research can be open to other teams, in order to collect data quickly in a web based data form, getting real time results after each data submission.

**CHIVA-LASER: OFFICE-BASED AMBULATORY HEMODYNAMIC PROCEDURE FOR CONSERVATIVE TREATMENT OF VARICOSE VEINS**

Puskas A, Fazakas IGy, Varga-Fekete T, Balogh Zs  
*Angio Center-Vascular Medicine, Targu Mures, Romania*

*Background/aim:* The CHIVA strategy is based on hemodynamic shunt definition with duplex ultrasound and classically consists of office-based surgical disconnection of the escape point (SFJ/SPJ) and/or the varicose branch(es) in local anesthesia. Our aim was to study the efficacy of short-segment endoluminal laser closure of SFJ/SPJ instead of surgical ligation in combination with surgical disconnection of the branches if needed.



**Methods:** 117 patients were evaluated before and 3-6-12-24 months after the ambulatory treatment of GSV/SSV truncal varicosity with CHIVA strategy using endoluminal double ring radial laser (Biolitec-Leonardo) for SFJ/SPJ short segment closure instead of surgical incision and ligation. The thermal endovenous closure was done in close proximity to the superficial epigastric vein which was left open as washing vessel. In 70% of the patients a later additional cosmetic sclerotherapy was performed for distal remnant varicose or reticular veins. General data (age, gender), clinical (VCSS score, C classes) and ultrasound parameters (average diameter of GSV taken from 3 points, residual reflux at the groin and eventual thrombophlebitis of GSV/SSV) were recorded and compared.

**Results:** The mean age was 51 years and 62.4% were women. The GSV was involved in the vast majority of the cases. 89,6% were in advanced clinical stages (C3-C6, C=3.9 and VCSS=9.2 on average). In 67.5% the duplex defined hemodynamic shunt type was 1+2 needing laser crossotomy and branch disconnection. The average length treated with laser from the junction was 11.4 mm. The applied mean energy was 1974.5 J/12.5W. The mean follow-up period was 18,4 months. The GSV diameter reduction was significant (from an average of 8,5 mm to 3,8 mm). There was also a significant clinical improvement after 3-12 months (C stage reduction from 3,9 to 2,1 and VCSS from 9,2 to 4,3). We found a 100% ulcer healing rate in C6 stages. Truncal GSV thrombophlebitis below the laser closure level was found in 16% with complete resolution after 3-6 months in the vast majority of the cases. Residual reflux at the groin was present in 7.6% without clinical signs of recurrence compared with 26.7% in our CHIVA- classic series. ( $p<0.0005$ )

**Conclusion:** The results of classic CHIVA strategy could be significantly improved applying endoluminal double ring radial laser closure of the escape point at SFJ/SPJ together with a short segment closure of GSV/SSV below. CHIVA-laser procedure seems to be a safe, efficient, ambulatory method for truncal varicose vein treatment with preservation of GSV, shorter intervention time, simpler to perform, less groin residual reflux and better tolerated compared to classical surgical methods.

### MINIPHLEBECTOMY ACCORDING TO VÁRADY'S METHOD AS THE MOTHER OF AESTHETIC PHLEBOLOGY

Jaroslav Kalemba  
*Estmed Strzelce Opolskie*

The miniphlebectomy is one of the basic methods used in aesthetic phlebology. Based on his 25 years of experience, the author discusses the indications for miniphlebectomy, the manner of its implementation and possible complications. Special attention is paid to the use of miniphlebectomy in the so-called hybrid methods. He emphasizes that miniphlebectomy is a crucial element of

ablative endovenous procedures. He also presents miniphlebectomy as a procedure preceding sclerotherapy. In each case, he presents improvements that facilitate the implementation of miniphlebectomy.

The author indicates beginning to use Várady's method as a turning point in his career and the start of his adventure with aesthetic phlebology. In the author's opinion, aesthetic phlebology cannot exist without miniphlebectomy.

### COMBINATION OF EVLA, SCLEROTHERAPY AND MINIPHLEBECTOMY IN TREATMENT OF RECURRENT VARICOSE VEINS

Slavin D<sup>1</sup>, Parikov M<sup>2</sup>, Shamsutdinova I, Chugunov A  
<sup>1</sup> Kazan State Medical Academy, Kazan, Russia  
<sup>2</sup> Innovative Vascular Centre, Saint-Petersburg, Russia

The recurrence of varicose vein disease remains an important problem: there are around 15% of those patients in our daily phlebological practice. In 2018, we performed endovenous laser ablations (EVLA) in 53 patients with recurrent varicose veins. All interventions were performed on outpatient basis, under local tumescent anesthesia, using a 1560/1470 nm diode laser and different types of radial fibers (single-ring, two-ring, slim). In all patients, EVLA was performed together with sclerotherapy and/or miniphlebectomy of varicose veins. The combination of various treatment methods and the choice of the type of fiber depended on the preoperative ultrasound diagnostics, which determined the cause of the recurrence and the tactics of the intervention. In the postoperative period all patients were prescribed compression stockings (II class) for 2-3 weeks and low molecular weight heparin in a prophylactic dose for 5 days. Control ultrasound examinations were performed on the 1st, 7th, and 14th day and after 6 months.

According to our data, the most frequent cause of recurrence after open surgery was "neovascularization" in the crossotomy zone and incompetent perforating veins on the thigh. The purpose of the repeated intervention was to eliminate all sources of reflux and incompetent veins. For this purpose it was necessary to position the fiber as close as possible to the reflux source and to use the possibilities of EVLA in all accessible, relatively straightforward veins. The remaining segments of the recurrent veins were closed with echoguided foam sclerotherapy or miniphlebectomy. Often it was necessary to install several fibers depending on the anatomical structure, as well as to perform sclerotherapy in different areas. If there was a pathological stump of GSV/SSV more than 2 cm, it was closed with slim radial fibers or standard one and two-ring ones depending on the length of the stump and the presence of tributaries. In cases where there were residual trunks of GSF, SSV or AASV laser ablation was performed using standard methods in combination with miniphlebectomy or sclerotherapy. In doing so, we have always tried to perform EVLA where possible, avoiding sclerotherapy in relatively straight veins





including extrafascial segments. In case of recurrences after primary EVLA (recanalization or incompetent AASV) we repeated the procedure and used higher linear energy density in cases with recanalization. EVLA was performed immediately, without waiting for clinical manifestations of varicosity.

As a result of treatment, the obliteration of recurrent veins was achieved in 100% of cases. Such complications as endothermal heat-induced thrombosis and deep vein thrombosis were not noted. One recurrence was detected during follow up (6 months), no recanalization after EVLA was observed.

*Conclusion:* endovenous laser ablation in combination with sclerotherapy and miniphlebectomy is an effective and safe method of treatment of recurrent varicose veins.

### **MINISURGERY OF VARICOSE VEINS**

Zoltán Várady

*Venenklinik Frankfurt, Germany*

The majority of patients suffering from varicose veins are women, and this implies that not only medical but also cosmetic aspects have to be considered in therapy. Often stripping is combined with more or less large and numerous cuts to extract branches. In many cases scars after traditional surgery are more annoying for the patient than the varicose veins before. Besides that many develop edema because of the destruction of lymphatic vessels. It is therefore of the greatest importance to have one method in mind which contains both aspects. Many thought of removing varicose veins through micro-incisions. Using more or less appropriate small hooks they tried to extract varicose veins

without considering that veins are fixed in their surrounding tissue. This means neither the technique nor the instruments used were suitable to get any further with this problem. This is the first method based on surgical principles together with matching surgical instruments, the Phlebextractor and the Phlebodissector, by which modern mini-surgery of varicose veins could be established.

### **UNWANTED VEINS OF THE FOREARM AND THE HAND: TREATMENT OPTIONS**

Alexander Flor

*Vein practice at Private Clinic Döbling, Vienna, Austria*

Since 2006 we have been treating unwanted veins of the forearm and the back of the hands. With age skin becomes thinner, age spots appear, and subcutaneous tissue becomes thinner, so that the veins of the back of the hand become more prominent.

Another group of patients are sporty young people especially women, running, exercising, going to the gym. We have a defensive approach and always ask our patients if and why they do not like their veins. Photographic documentation is made. Malignancy or lack of veins in the cubita would be exclusion criteria.

Three techniques will be presented:

In most of the cases, especially in thin dilated veins and tortuous veins of the back of the hand FOAM sclerotherapy is the technique of choice. Concentration is 2- 2.5% Polidocanol, a SYRIS V900 Cross Polarisation is used for augmented reality. Treatment time is about 5 minutes for both hands, repeated after one week and three weeks. Induration might occur.

Severe side effects like thrombosis have never occurred.

Thick-walled veins of the hand are treated by miniphlebectomy. Even when done under tumescent anesthesia it might be a bloody procedure. Skin nerves might be damaged.

Endolaser treatment is our third treatment option, preferably for long, stretched, thick-walled veins of the forearm. The procedure is very effective, yet time-consuming. A short video will be presented.

Treatment of the veins of the hand and the forearm is part of aesthetic phlebology. Therefore every phlebologist should know the basic treatment options.

### **MICRO-“SURGERY” OF SPIDER VEINS**

Zoltan Böhm

*Venenklinik Frankfurt, Germany*

The usual treatment of capillaries is sclerotherapy. I do agree with that. Pigmentation nevertheless remains because coagulations can by no mean removed totally. Because the results were often poor several other methods were tried.

Certain circumscribed “large capillary convolutes“ - so called “venous mini aneurysms“ - and other specific forms often leave intense pigmentation, so that fundamental new ways ought to be found.

In varicosis the leg has a high venous pressure. Thus, the most important task is to remove the causing veins to lower the pressure. Only after that therapy of the capillaries can begin. The goal of multi-microinterruption is to cut the veins into small pieces. Capillaries in connection with these will collapse after this and mainly disappear. The remainders are sclerosed.

Classification of spiderveins by their colour: - red, - blue. What is the difference? The difference is in their diameter: -red: 0.2 mm or less, blue: 0.4 mm or more. this means that in red capillaries the blood velocity is higher than in blue capillaries.

Incisions are made very close to each other, practically cutting apart the tiny branches. The blood drains off the small vein pieces are deprived of blood supply, collapse and become reabsorbed. If some very thin veins remain, they can be sclerosed without problems, no pigmentation will occur. Injections have to be made deeper to prevent capillaries from getting contracting and becoming invisible.



### CLACS – THE NEW MODALITY IN TREATMENT OF TELEANGIECTASIAS

Vladimir Kovács<sup>1</sup>, István Munka<sup>2</sup>, Lenka Bajuzikova  
<sup>1</sup>*Blumental clinic, Bratislava, <sup>2</sup>Medicentrum Zvolen,  
Slovakia*

Cryo-Laser and Cryo-Sclerotherapy is a treatment for leg teleangiectasias by combining transdermal laser effect and injection sclerotherapy, all under skin cooling and the use of a digital vein detection device - Venviewer to visualize hidden feeder veins. The 1064nm laser causes a selective photothermolysis which damages the vein wall. The vein's lumen gets smaller. On a second procedure, sclerosing agent is injected where the vein is still open.

**Materials and Methods:** Patients were treated with CLaCS procedure.

**Results:** Partial or unsatisfactory outcome was observed in 5% patients. The problematic persisting small vessels we treat with shorter wavelength. By varying the pulse duration we can perform slowly heating and coagulation of the blood vessels, not only intercellular edema and lesion of endothelial elastic fiber.

**Conclusion:** This more comprehensive treatment of teleangiectatic lesions guided by a digital device and combining two laser wavelengths.

### IMPROVED SCLEROTHERAPY BY TRANSILLUMINATION

Rüdiger Damisch

*Institute of Vein- and Laser Therapy, Salzburg, Austria*

From time to time one comes to a point where sclerotherapy does not have the desired effect. One of the causes can be that the subcutaneous veins, especially the feeding vessels of a spider vein or a reticular vein network are not visible. These become visible with the aid of devices for visualization of these vessels and the challenge is to puncture precisely in the right place and to inject the sclerosant solution as liquid or foam. Among all devices on the market e. g. the projection of near infrared on the skin and similar devices, transillumination shows a significantly easier and safer access to the vessels. Due to transillumination, vascular structures are visible and accessible for puncturing down to a depth of 1.0 cm and become visible as a shadow on the surface of the skin. With increasing experience, the two-dimensional images are seen as three-dimensional. You can also differentiate between competent or incompetent valves or vein segments and use it for mapping veins prior to operations. Pictures of areas of difficult structures will be shown to compare the difference between the naked eye and transillumination.

### TREATMENT OF UNAESTHETIC PERIORBITAL VEINS WITH 1064 NM LONG PULSED ND: YAG LASER

M.A.Parikov<sup>1</sup>, D.A.Slavin<sup>2</sup>, E.A.Gavva<sup>1</sup>, U.R.Dolidze<sup>1</sup>  
<sup>1</sup>*Innovative Vascular Centre, Saint-Petersburg, Russia*  
<sup>2</sup>*Kazan State Medical Academy, Kazan, Russia*

**Aim:** Unaesthetic periorbital veins are common cosmetic problem for women. Worldwide scientific literature has accumulated a very scarce experience in this field consisting of very few publications dedicated to the treatment of this zones with sclerosants. However, the resulting post injection hematomas lasting two weeks and necessity of plenty treatment sessions do not allow us to consider this problem solved. We successfully treated this kind of veins with Nd:YAG laser, wavelength 1064 nm.

**Materials and methods:** 136 patients (134 females and 2 males), average age  $34.7 \pm 8.1$  (21-59), were treated from December 2016 to May 2019. Periorbital veins were the problem under both eyes in 63.2% of cases (n=86). At the same time, 23 patients experienced cosmetic discomfort due to periorbital and temporal veins (16.9%), 7 pts – periorbital, temporal and cheek veins (5.1%), 2 pts periorbital and cheek veins 1.5%. In 28 cases not only veins under the eyes were the problem but also veins above upper eyelid (20.6%). In 2 cases veins were founded after plastic surgery (1.5%).

We did not use local anesthetic predicting possible vein spasm. All procedures were performed with local cooling (cryocooling under -30 degree Celsius), Nd:YAG Almalasers Harmony XL Pro 1064 nm LP, spot 6 mm. After skin cooling for 1-2 seconds we delivered an impulse, pulse duration 15 ms, fluence of 120-130 joules/cm<sup>2</sup>, per every 6 mm along the vein. After vein spasm and its visual disappearance we applied corticosteroid cream and recommended to prolong applications twice a day for 5-7 days. Control examination was recommended four weeks later.

**Results:** In 87.5% of cases (n=119) the initial veins disappeared. In 15 cases (11.0%) a few zones along the vein were repeatedly treated with full vein resorption some time later. We registered side effects such as treatment zone edema for 2-10 days in 58.8% (n=79) of the cases, which regressed spontaneously. No skin damage, burns, paresthesia and hyperpigmentation were registered.

**Conclusion:** Nd:YAG laser with 1064 nm wave-length is a very effective and safe method for the treatment of periorbital, temporal, cheek veins.



### VENOUS INSUFFICIENCY CAUSING ALTERATION OF SKIN BARRIER FUNCTION AND MICROBIOME PROTECTION

Judit Daróczy,

*Istenhegyi Magánklinika Zrt. Budapest, Hungary*

Patients with venous insufficiency commonly develop complications which can result in significant morbidity. Not only venous ulceration, but other complications may arise including stasis dermatitis. The normal epidermis is the major barrier of the body to the outside, and is constantly confronted with microbial, chemical and physical insults. There is a balanced interplay between the host and resident/or transient bacterial populations.

The normal skin barrier and the microbiota act like a shield. This balance is continuously affected by host and environmental factors that alter the composition of skin microorganism communities and the host skin barrier function. Altering this equilibrium is called dysbiosis. Not only extrinsic factors but intrinsic factors such as venous insufficiency can imbalance the healthy skin microbiota.

Patients with stasis dermatitis have a disrupted epidermal barrier, making them susceptible to contact sensitization and different infections. Disorganization of epidermal structure including modified lipid composition, lead to weakening of the skin barrier, allowing entry of environmental allergens, and pathogen microbials. Stasis dermatitis is characterized by erythema, scaling, weeping, crusting. This condition can be made worse by bacterial superinfection or by contact dermatitis caused by the many topical treatments (emollients, antibiotics) often applied. Stasis dermatitis progresses to skin ulceration.

The goal of treatment for stasis dermatitis is to prevent the condition from progressing, to promote circulation, restore the normal skin barrier and microbiota function.

### APPLICATION OF THERMAL ABLATION IN TREATMENT OF PATIENTS WITH SUPERFICIAL VEIN THROMBOSIS OF LOWER EXTREMITIES

Serhii Shchukin, V Goncharov, A Sivolap, V Maslov

*LTD "Medical Center of Modern Phlebology",  
Kiev, Ukraine*

**Background:** Superficial vein thrombosis (SVT) in many countries is the most common complication of varicose disease of the lower extremities, the frequency of which can reach 30%. In half the cases, SVT can have a recurrent nature. Ascending forms of SVT can lead to deep vein thrombosis and pulmonary embolism. Conservative treatment does not always stop the process of thrombosis and does not ensure the patient from thromboembolic complications.

The problem of surgical treatment of SVT in varicose veins has no definitive solution. There is insufficient information on the use of minimally invasive technologies in the treatment of varicose disease complicated by SVT.

**Aims:** We wanted to explore the opportunity of using endovascular laser treatment (EVLT) and radiofrequency ablation (RFA) in the treatment of varicose disease of the lower extremities, which is complicated by SVT.

**Patients:** There are the treatment results of 86 patients (70% women, mean age  $56 \pm 13.5$  years) who were operated on from 2013 to 2018 and analyzed for the safety and efficacy of RFA and EVLT. All patients were examined by ultrasound duplex scanning (UDS). In 74 (86%) cases, SVT was observed in the great saphenous vein (GSV) and its tributaries, in 12 (14%) - small saphenous veins (SSV) and its tributaries. In 49 (57%) cases, SVT spread to the thigh. In 76 (88%) patients (Group A), the proximal border of thrombotic masses was not closer than 10 cm from the sapheno-femoral junction (SFJ). In 10 (12%) patients (group B), we observed the ascending forms of SVT, including 2 patients with thrombosis SPJ and 8 patients with thrombosis SFJ. The timing of SVT ranged from 2 weeks to 4 months. In 45 (62.5%) patients, venous insufficiency was C 3, 30 (35.7%) - C 4-5, 11 (1.8%) - C 6 (CEAP).

Patients of group A were operated on in the days after treatment. 30 (35%) patients were treated with RFA. The diameter of the GSV in the SFJ area was  $14.7 \pm 4.8$  mm. For 46 patients (65%), EVLT was performed. The diameter of the GSV in the SFJ area in this group was  $11.5 \pm 4.2$  mm, the diameter of the SSV in the SPJ region was  $9.3 \pm 3.2$  mm.

Patients of group B were informed about the necessity of hospitalization in the Department of Vascular Surgery for surgical treatment (crossectomy), but they gave informed consent to outpatient treatment under our supervision. The risk of hemorrhagic complications of anticoagulant therapy in each patient was assessed. Patients received anticoagulant therapy (ksarelto 10-20 mg per day) for 1 to 2 months. We performed UDS on day 3, 7, 10, 15, then at 1, 1,5 and 2 months. In the period from 3 weeks to 2 months, we observed a recanalization of the proximal parts of GSV (8 patients) and SSV (2 patients), which allowed us to perform thermal ablation.

**Methods:** All patients were examined with UDS. All patients underwent surgery under tumescent anesthesia with ultrasound control. The puncture veins were performed immediately proximal to the thrombotic masses.

RFA was performed according to the VNUS Closure FAST technique. For the EVLT, a diode laser of 1470 nm (Biolitec) and 2-ring radial fiber was used. EVLT was carried out at a power of 9 W, with automatic traction of the laser fiber (0.7 mm / s); LEED - 130 J / cm.

Additional intervention was performed in 24 (27%) patients using miniphlebectomy of varicose veins by Várady, and for 18 patients (21%) thrombotic mass removal (phlebocentesis) through punctures was performed.

In all cases, surgical treatment was carried out under the conditions of "office surgery". After 30 minutes after the operation, the patients left the clinic on their own. All patients received anticoagulant therapy for 10 – 20 days.



Compression stockings of class 2 patients were worn daily for 1 month. Pain syndrome was not expressed in the postoperative period. A single reception of non-narcotic analgesics was required in 12 (14%) patients who underwent miniphlebectomy.

*Results:* UDS was performed for all patients the day after the operation, one week later, after 1, 3, 6 months and then annually. During the entire follow-up period, there were no cases of deep vein thrombosis or pulmonary embolism. Complete obliteration of the GSV was recorded for all the patients. For 5 (5.8%) patients after RFA, endothermal heat induced thrombosis (EHIT) of SFJ class 1 (according to Kabnick) was noted, in 1 (1.7%) - 2 classes. For one patient (1.7%) after EVLT, EHIT of SFJ class 1 was noted. This required prolongation of anti-coagulant therapy for up to 15 days.

One year after EVLT, the vein on the laser-treated site was not visualized with UDS. For patients after RFA at the same time of observation, the GSV was visualized as an echogenic strand of diam. 3-4 mm in diameter.

During the period of 3 to 6 months, recanalization of those parts of the veins that were affected by the thrombotic process was noted. 69 (80%) patients performed ultrasound guided foam sclerotherapy of such veins (polidocanol foam 3% 3-6 ml per session).

*Discussion:* After performing traditional operations with SVT (crossectomy, stripping, excision of varicose veins), patients need hospitalization, prescription of narcotic analgesics, and post-operative rehabilitation. The absence of scars after RFA and EVLT gives the maximum cosmetic result in comparison with "open" operations.

*Conclusions:* RFA Closure FAST and EVLT using a 1470 nm diode laser and 2-ring radial fiber with acute SVT of the trunk and inflows of GSV is a safe, minimally invasive alternative to traditional surgical treatment. The use of this technique makes it possible to treat patients with acute SVT in outpatient settings, to significantly shorten the period of incapacity for work and further rehabilitation, and significantly improve the cosmetic effect of surgical treatment.

**"LASER CROSSECTOMY",  
THE STATE-OF-THE-ART IN EVLA  
Single Centre experience using radial fiber  
in more than 3000 EVLA performed**

Petar Dragic, S Andric  
*Clinic "Dr Dragic", Belgrade, Serbia*

*Objectives:* We have used our experience of 3000 EVLA cases to improve the procedure. Technological development of the new generation of endovenous fibers with radial laser beam has led to the improvement of the endovenous laser ablation technique (EVLA). Now it is possible to make total ablation of the vena saphena magna (VSM) without tumescent anesthesia (TLA) using high power diode laser (HPD) in a puls moden and radial fiber.

The effects of this technique could be compared with other endovenous techniques which use TLA. The aim of the paper is defined as the evaluation of safety and efficiency of endothermal ablation of the saphenous vein using HPD without (TLA).

*Method:* We treated 35 incompetent VSM using laser ablation with HPD laser and radial fiber procedure. Our aim was to create a painless procedure without using TLA. We used high energy of 120 w delivered in short pulses with duration of 10 ms and 100 ms off time. Pull-back speed was on average 1 cm/sec and delivered energy was about 15-20 J per cm. A high amount of power (120w) and short pulse time of 10 ms creates has not only thermal but also mechanical effects on the intimal layer of the vein wall. The momentum of laser beams of short pulses create also a hit to the endotelial cells of the vein wall.

Ultrasound checking was performed one day, two weeks, six months and one year after the procedure. We measure pain during the intervention, patient satisfaction with and after the procedure.

*Results:* We treated 35 incompetent VSM using EVLA with HPD laser and radial fiber but without the tumescent anesthesia procedure. All the treated veins showed total occlusion during the first as well as other ultrasound examinations. We observed no significant differences in relation to clot extension into the deep vein in the monitored groups. In 3 patients from group I, we noticed a small clot extension in VFC (clot extension max. 1.7 mm ranging from 0.2 to 1.7; mean 0.9 mm), while in two patients from group II we diagnosed clot extension in VFC maximally up to 1.5 mm. It was noticed that in group I thrombotic masses were completely tied to VSM wall on saphenofemoral border, while in group II thrombotic masses were tied to the wall distal from VSM junction, i.e. at the place of catheter positioning. Proximal or extended clot part was not tied to VSM wall. During control examination after four weeks in both groups a clot retraction from VFC was noted. Mean time needed for endothermal ablation was around 8 minutes with no adjuvant procedures. The intervention was assessed as easily bearable (63 patients), moderately bearable (8 patients), difficult (1 patient), and unbearable (0 patient).

*Conclusions:* Clot extension within VFC lumen during EVLA (radial fiber) procedure on VSM with  $\leq 1$  cm diameter is not related to the level of laser catheter positioning within VSM lumen. Clot extension was more significantly dependent on blood flow characteristics than on the level of catheter positioning within VSM lumen. In order to confirm the final statement, further examinations are needed.



**HYBRID AASV-GSV VEIN:  
INCIDENCE AND ANATOMICAL  
PATTERN**

Oksana Riabinska, Rustem Osmanov, Lyudmila Roshina,  
Alexandr Tolstov, Vitaliy Shtogrin  
*Institute of Veins, Kharkiv, Ukraine*

*Objectives:* Upon ultrasound visualization of a single saphenous trunk (SST) joining the SFJ, it is identified either as GSV or AASV (in the event of GSV hypoplasia). However, a detailed study of ultrasound anatomy allowed the detection of venous trunks, which do not all have features of the above-mentioned veins.

*Goal:* Anatomic identification of SST, which joins SFJ and which has AASV features in the proximal thigh.

*Methods:* Detailed duplex ultrasound examination was performed in 978 limbs with SFJ incompetence. We further selected 118 limbs (12.0%) with SST joining SFJ having AASV features based on the following criteria: projection over the deep vessels in proximal thigh and “empty” E-point; and characterized them. We assessed the configuration and length of the saphenous trunk, and the integrity of a fascial compartment.

*Results:* Among 118 limbs with SST identified as AASV below the groin area, 53 (5,4%) saphenous trunks had short interfascial segment (proximal thigh), typical for AASV. However, in 65 limbs (6.6%), saphenous trunk was longer than the proximal 2/3 of the thigh, and in all cases it had frontal curvature in the distal thigh segment, after which the location of the studied saphenous trunk was typical of GSV. The total length of the interfascial part of the saphenous trunk in the second group varied from thigh length to whole leg length, including the curvature zone, which was located between fascial layers. In all 65 limbs GSV was present as a tiny vessel (1-2 mm in diameter) in a the groin area.

*Conclusions:* In 6.6% of limbs with GSV incompetence SST joining SFJ had the “hybrid” course, being located in the proximal 1/3-2/3 of the thigh as AASV, and more distally, after a typical curvature in the frontal direction, as GSV.

**ENDOVENOUS TREATMENT  
OF POST-SURGICAL VARICOSE  
VEIN RECURRENCE**

Imre Bihari, Peter Bihari, George Ayoub  
*A+B Clinic, Budapest, Hungary*

Recurrent varicosity patients who previously had classic surgery are a high percent of every phlebological practice. In many recurrent varicosity cases it is recommended to redo the surgery. Endovenous interventions, as in primary cases, seem to be a good solution for this problem. In the following paper we describe our experience in endovenous interventions.

- There are considerations in the treatment of these cases:
- US examination must be meticulous because of the multiple source possibilities
  - US examination is disturbed by the scarring of the previous surgery
  - puncture through the scar of former surgery is more difficult
  - saphenous stump is short
  - in many cases there is no saphenous stump only neo-vascularisation, which is typical for recurrency, but very rare in primary cases
  - result of perforator vein treatment is worse than that of saphenous junction and stem
  - usually different ultrasound guided therapeutic modalities are used, but the order of usage is important because after the first intervention the US picture is blurred

The benefit of endovascular treatment of recurrent cases are: fewer complications, less pain, blood loss, lymphatic damage, and faster surgery and convalescence.

The reoperation of recurrent cases is more difficult than that of primary varicosity. It is known that recurrences after redoing operations are higher than after primary surgery. This was also found in our cases. Surgical treatment of recurrent varicosities is difficult with both surgical and endovenous methods but we found the endovenous solution better.

**MODERN OPPORTUNITIES OF ENDOVASCULAR  
TECHNIQUES IN SOLVING THE PROBLEM  
OF PELVIC PAIN.  
WHEN, WHY, HOW.**

Chernukha LM, Guch AA, Kondratyuk VA,  
Vlasenko EA, Bobrova AO  
*National Institute of Surgery and Transplantology,  
Ukraine*

The Department of Surgery of Major Vessels and the Department of Endovascular Surgery have had the experience of treating more than 100 patients with pelvic pain in the past 5 years, more than 70% of whom had pelvic congestion syndrome (PCS) and 16% of whom had “two-level varicose disease” (PCS and varicose veins (VV) of the lower limbs or recurrent varicose veins of the lower limbs.

*Aims:* The aim of the study was to identify the causes of pelvic pain and explore the possibility of using endovascular techniques in the treatment of pelvic congestion syndrome.

*Materials and methods:* Examination of the blood flow in the ovarian and internal iliac veins in 70 women with pelvic pain was carried out. Color duplex scanning with Valsalva test was performed for the pelvic and subcutaneous veins reflux detection. Transvaginal ultrasound was performed for investigation of additional gynecological pathology. Phlebography and computed tomography were performed to exclude or confirm May-Turner and Nutcracker syndrome.



**Results:** Ultrasound signs of pelvic venous insufficiency were dilated veins of myometrium >4 mm, ovarian veins >8 mm, reverse blood flow during the Valsalva test. Varicose veins (VV) of the perineum were noted in 46 (65.22%) patients, in 30 (43.48%) VV on the thigh's medial and posteromedial surface were observed. The blood reflux on the left ovarian vein was recorded in 54 (78.26%) cases, on the both the right and left ovarian vein - in 15 (21.74%). In one patient, additional gynecological pathology was observed - adenomyosis, clinically manifested by persistent hemorrhagic vaginal discharge, dyspareunia and pelvic pain after a long stay in an upright position. The main method of treatment is embolization of the ovarian vein using spirals, performed on 56 patients, 7 of them (12%) noted the resumption of pelvic pain.

Endovascular methods of correction of pathological venous reflux in ovarian veins were used in 14 patients (20%), in 8 of them (57.14%) laser ablation with 2ring radial fiber, in 6 (42.86%) - radiofrequency ablation. In one case, 2 weeks before endovascular intervention, X-ray endovascular ablation of the uterine arteries was performed. In all patients with varicose veins endovenous laser ablation of VV was performed.

**Conclusions:** Elimination of the pathological venous reflux in ovarian veins may be suggested as the method of preventing of VV recurrence caused by pelvic venous hypertension.

#### **EIGHT YEARS OF NON-SAPHENOUS VEIN ENDOVENOUS LASER ABLATION WITH RADIAL FIBER**

MA Parikov<sup>1</sup>, DA Slavin<sup>2</sup>, EA Gavva<sup>1</sup>, UR Dolidze<sup>1</sup>  
<sup>1</sup>*Innovative Vascular Centre, Saint-Petersburg, Russia*  
<sup>2</sup>*Kazan State Medical Academy, Kazan, Russia*

Since 2011 we have used ELVeS Radial technology for the vein trunk ablation. Most of all for the ablation of the great saphenous vein, anterior accessory saphenous vein, small saphenous vein, thigh extension of small saphenous vein. The high success rate of the procedure and almost painless postoperative period ensure that we chose endovenous laser obliteration as a safe and reliable method. However, with more and more experience we have broadened indications for this procedure including Thierry and other perforators, long postoperative great saphenous and small saphenous vein stumps, tributaries of the thigh and calf.

**Materials and method:** From 2011 to 2018 we performed EVLA on 4000 lower extremities. Among them EVLA of 85 Thierry perforating vein, 54 small saphenous and great saphenous long postoperative stumps, 360 lower extremities which required ablation of several perforators and 445 cases included EVLA of tributaries. This demonstrates that significant part of the insufficient non-saphenous veins can be obliterated with ELVeS technology. In the beginning we used 1Ring and Slim fibers, although, the most convenient option in the end is combination of the short introducer and 2Ring

fiber which has the highest success rate and availability of higher energy ablation without carbonization. Modern 2Ring Slim and Swift fibers allow us to spare introducers and provide higher energy vein obliteration.

**Results:** There were no cases of severe complications or burns. Recanalization occurred in less than 2% (n=75) of cases due to low LEED and usage of slim fibers. Mostly in cases of the ablation of long postoperative great saphenous stumps and perforators. Treatment of tributaries with LEED <140 J/cm in 30% of cases led to mild temporary hyperpigmentation which lasted 6-12 months.

**Conclusion:** Treatment of vein segments such as extrafascial veins, perforating veins, postoperative GSV and SSV stumps with radial fiber laser ablation allows us to reduce the traumatization of procedure, the amount of sclerotherapy or extent of microphlebectomy and provide high efficiency of procedure. The best EVLA results can be achieved by high LEED on strategic vein segments.

#### **THE ROLE OF ECO-GUIDED FOAM IN THE VARICOSE ULCER TREATMENT**

Isaac Yopan

*CEMEVA (Centro Médico De Várices, Spanish for  
Varicose Veins Medical Center) Morelia, Mexico*

In Mexico 70 – 80% of the over 60 year – old population, suffer from varicose veins. This pathology is more common in women at an earlier age (30 – 40 years old) due to pregnancy and being overweight. In men, this problem appears at age 40 – 50 because heavy lifting efforts and body aging. It can also be originated from genetic causes and a sedentary lifestyle. From the age of 60, the incidence is equal in both genders. We are talking about a disease detonated by hypertension and dilatation of the vein walls.

The lack of venous return is the main cause of the development of venous ulcers in the lower limbs. These alterations make the skin to be more vulnerable to any kind of traumatism and to get an ulceration. The vast majority of these ulcers occur in the leg's inner region approximately 3 cm (1.2") above the medial malleolus.

In our clinic the main reason for our patients with ulcers to seek treatment is for functional reasons: i.e. to cease pain (80%) more than for aesthetic reasons (20%). The majority of people that come to our clinic are elderly people with ulcers for more than 30 years approximately, they do not care about the aspect of their skin, and they only want a cure for their symptoms. On the other hand, we have had young women (35 years old) with ulcers after pregnancy. Every patient undergo an examination with Doppler ultrasound for these benefits: noninvasive, the simplicity of perform, it doesn't need to be performed in the operating room or require anesthesia and could be performed as many times as necessary. The treatment of sclerosis with foam guided by ultrasound of the saphenous veins has demonstrated good results, relieving symptoms and reducing scar of the skin.



**POSSIBILITIES OF ENDOVENOUS LASER COAGULATION IN THE TREATMENT OF PATIENTS WITH CONGENITAL ABNORMALITIES OF THE DEEP VENOUS SYSTEM OF THE LOWER EXTREMITIES**

LM Chernukha, GG Vlaykov, OV Kashyrova, AO Guch, OA Vlasenko, VA Kondratyuk, AO Bobrova  
*Shalimov's National Institute of Surgery and Transplantation to NAMS of Ukraine, Kiev*

Venous forms of congenital vascular malformations (VCVM) range from 49 to 80% of all forms of CVM. As studies show, pronounced pathology of the deep venous system is observed in every 3 patients among VCVM.

*Aim:* To determine the possibility of using endovenous laser coagulation in the treatment of anomalies of the deep venous system of the lower extremities.

*Material and methods:* In the period from 2015 to 2018 under the supervision were 51 patients with VCVM with a pathology of the deep venous system, of whom 24 (47%) men and 27 (53%) women. The age of patients varied from 8 to 43 years. The average age was  $27 \pm 4$  years. The main complaints of the patients were the presence of pain, a feeling of pain in the limbs, swelling, and the presence of varicose veins. Examination methods - color duplex angioscanning, phlebography and arteriography of the lower extremities (if indicated). The truncular (T) forms of VCVM were detected in 17 (33.3%) patients, the extratruncular (ET) forms - in 21 (41.2%) patients, the T and ET forms - in 13 (25.5%) patients. According to color duplex angioscanning, "sources" and confluence points (to the iliac veins) with multiple connections to the hypoplastic deep venous system were determined. In overwhelming number of patients, the defeat of the deep venous system was limited only by segmental hypoplasia of the deep venous system in the area of the presence of CVM.

*Results:* In the presence of T forms, according to color duplex angioscanning, the sources of reflux were determined, as well as the conditions for the possible closure of the venous trunks using endovenous laser coagulation (ELC). In the case of ET forms, X-ray endovascular obliteration (EO) of microfistulas was used in 11 (33%) patients to reduce arterial inflow, then ELC was performed. In the case of the presence of combined forms of CVM at 1 stage was performed EO of microfistulas, then ELC. The ELC technique suggested the closure of the "marginal" vein and anomalous veins of the deep venous system. The method involved the segmental implementation of ELC (in stages) or throughout, depending on the location and extent of the lesion. Tumescence anesthesia was used. In most cases, ELC was supplemented with compression sclerotherapy. All patients were operated in 2-4 stages. Terms between stages lasted for 2-3 months. Given the proximity of the arteries and nerve trunks, as well as to prevent fascio-compression syndrome, it is necessary to correctly perform tumescence anesthesia on the lower leg.

The obligatory moments of the operation were the presence of constant contact of the patient with the doctor, control of pulsation on the peripheral arteries of the limb.

*Conclusion:* The proposed approaches allowed the achievement of satisfactory results in all operated patients. The complete closure of ablated veins was noted.

**QUO VADIS VARICECTOMY?**

István Rozsos, Gergely Vadász, Melinda Gadácsi  
*Theta Centers: Budapest, Pécs, Théta Vascular Team*

With the advent of endovenous techniques, varicose vein surgery has changed significantly over the past 15-20 years. Minimizing surgical techniques were already sought-after, evolving from the practice of large incisions named after Madelung, toward smaller incisions and smaller scars, with the help of the Smetana and Várady methods. But the only tool for the removal of the great saphenous vein so far, has been the stripping method, introduced by Babcock. However, this stable strategy was first disturbed by the appearance of cryo-varicectomy, but the fact of stripping and the traumatization of the surroundings were still very much happening in these cases.

Endovenous laser therapy and the advent of radio frequency venous catheters have fundamentally shifted thinking - even though the effects of the initial difficulties and skepticism of the early period can still be felt sometimes - acceptance of the endovenous principle is becoming more natural.

This, of course, required all the improvements that made the technique safer - from the "competition" between the laser and the RF techniques, the patients emerged as victors, as safety and efficiency both increased. Along with the therapeutic tools, the diagnostic side has gone through incredible development: cabinet size - low resolution ultrasound devices with perfect image quality - shrunk to the size of a laptop.

From this analysis of the period, it became clear to everyone that the indication of conventional varicectomy was gradually being narrowed - the diagnostic and therapeutic expectations were changing greatly - also because of the compelling force of the patient's needs.

In addition to solutions within the mechanical vein, the search for adhesive-based methods has been a major success in terms of eliminating thermo-damaging effects.

In the 13 years since the first laser vein surgery in Hungary (September 23, 2005), in the projection of our 1700 surgeries, the development of endovenous surgery can be easily traced - from the high energy 980 diode laser to the more efficient generators and from plain laser fiber used with danger of perforation, to double ring - conical devices - and from heavy rf fibers to gracile devices with active heads of only a few centimeters.

In our presentation, we review the results of the past 13 years - and highlight future opportunities for development -



in addition to the easy-to-use, isolable, wireless US that has appeared in diagnostics, we present the Microwave venous ablation System. We were the first in Hungary to use this system in December 2018; this was a new step towards the future, and our expectations are not going away.

### **CROSSROADS IN PHLEBOLOGY: VALVE SALVAGE OR VEIN KILLING?**

Chris Ragg, Krastina Stoyanova  
*Videv, Angioclinic® Vein Centers, Berlin, Germany*

*Background:* Venous insufficiency (VI) is one of the most ignored diseases. Physicians' and people's belief is that 1) VI is mainly genetically determined, 2) there is no way to prevent it, 3) invasive therapy should be delayed as long as it has relevant risks. The introduction of endovenous modalities have reduced the risks, but overall expenses for invasive treatments are rising, and patients are still not offered effective therapy until they show serious problems or at least large varices. Current efforts are on the safety and patient comfort of endovenous methods, like with the second and third generation of vein gluing, the combination of sclerotherapy and compression film bandage, perivenous hyaluronan or novel protein-enforced microfoam. While it is good to improve ablation techniques, it may be much better to reduce the need for it, starting with the early stages.

*Studies:* Newer studies of our clinics, using broad-band high-frequency ultrasound (HFU, 16 – 32 MHz) reveal four different mechanisms of VI: First, a high incidence of vein valve defects in children - above 35% in the group of 6 – 8 year-old kids, most probably congenital. These lesions grow during adolescence and determine a primary pattern of vein disease. Repair is the only cause-related therapy. Second, pressure-mediated decompensation of valves is the next mechanism occurring in peoples' lives. Normalizing local diameters by perivenous fillers seems to have become an option. The third component is stasis-related, long-term valve degeneration, reacting well to preventive measures like physical exercise, compression stockings and venotonic/anti-inflammatory medication. Our studies on more than 1000 legs showed six different stages, from early hemodynamic disturbance to final loss of valve structures, with a new stage marker called "persistent aggregates". The fourth and final mechanism to occur - phlebitis - is more an accelerator of pre-existing valve damage than a primary cause.

*Conclusions:* Vein salvage means valve salvage. By the latest ultrasound analysis, there is a clear differentiation between which lesions need primary repair and which deserve proof-based prevention. Early diagnosis and treatment, as in dentistry, is the suggestion for the future.

### **RETURN TO THE FUTURE: 50 YEARS OF VASCULAR ULTRASOUND**

René Milleret  
*Vichy, France*

The first paper on vascular Doppler was published in 1969; Continuous wave Doppler units were available, first in non-directional devices, then with direction of the blood flow away or toward the probe: venous flow could be studied precisely and the diagnosis of deep and superficial venous insufficiency became more reliable. We introduced the first Duplex machine, offering imaging and simultaneous Doppler flow velocity measurements in 1981: it was called *Aggeion*, and was followed by other devices - diagnosis of venous thrombosis was then possible with ultrasound with a good level of accuracy.

We are now at the edge of a new revolution: therapeutic ultrasound, used to treat varicose veins transcutaneously. We have been working on such devices since 2005, using specific *HIFU* probes. *HIFU*: High Intensity Focused Ultrasound are already used clinically for cancer removal, glaucoma and other applications. 2 different approaches have been tested on animals or humans:

1/ *Thermal Transcutaneous Ablation* was developed from research which we Performed at Inserm in Lyon from 2005, and licenced to the French company *Theraclion®*. The *Echopulse®* device is a robotized instrument. The treatment is planned on an ultrasound image of the vein to be treated, which must be compressed by the probe. A segment of the volume of a grain of rice is heated at 85 degrees Celsius in 20 seconds. The process is repeated until all the pre-defined target has been heated. The probe incorporates a skin cooling system, but tumescent anesthesia is still necessary in the majority of patients. *Obermeyer* reported the first clinical results of this system and confirmed its safety and short-term efficiency for closing short segments, perforators, recurrences. With the existing device, it is not possible to ablate a saphenous trunk along its full length as it would take a very long time while the patient must stay motionless. Future improvements will open more possibilities.

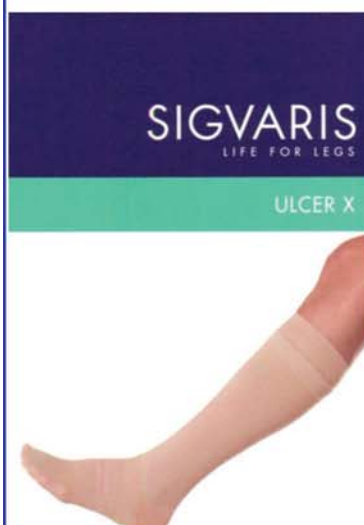2/ *Transcutaneous Cavitation devices* are studied in the same Inserm research unit: Lab Thau in Lyon, and the Vein Sound® team. Cavitation is a non-thermal biological effect of ultrasound. Pulses of HIFU cause rapid changes in tissue pressure, which in liquid blood generates micro bubbles. These cavitation bubbles oscillate and exert shear stresses on the surrounding tissues: the venous endothelium expand rapidly and then collapse. Before collapsing, the cavitation bubbles reflect the ultrasonic waves, generating more bubbles in a "Cavitation Cloud". The energy released ablates the endothelium and damages the media, a Sclero-like effect being achieved. The treatment is performed under Ultrasound imaging, it is faster than thermal ultrasound and painless: tumescence is not necessary. The full length of saphenous trunks can be treated, as well as superficial varices as they have less risk of skin damage. This technique has been tested on sheep, and clinical studies are expected to begin before 2020 .

*In conclusion*, we believe that these transdermal techniques will replace endovenous techniques in the near future.



# SIGVARIS ULCER-X

## új lehetőség a vénás lábszárfekély kezelésében



A vénás lábszárfekély gyakori kísérője a krónikus vénás megbetegedéseknek, gyakorisága kb. 2% a lakosság körében. A már kialakult fekély hatékonyan gyógyítható kiegészítő kompressziós terápia segítségével. A sienai egyetem sebészeti tanszéke által készített tanulmány szerint

- a SIGVARIS ULCER-X kit 96,2%-os gyógyulási rátát mutatott a pólyák 70%-os rátájával szemben,
- a mintegy 4 cm átmérőjű fekélyek kétszer gyorsabban gyógyultak a SIGVARIS termék használata esetén, mint a rugalmas pólyával,
- a fájdalom, a diszkomfort-érzet és a láb állapotából fakadó hétköznapi gátlások lényegesen csökkentek a SIGVARIS ULCER-X használata esetén,
- a SIGVARIS ULCER-X használatkor az éjszakai fájdalom teljesen megszűnt, míg a rugalmas pólyát használók 40%-a panaszkodott éjszakai fájdalomról.

Mi is hát ez a SIGVARIS ULCER-X kit?

A készlet tartalmaz 2 db igen csúszós fejű, többi részén pamutból készült alsó harisnyát, mely hozzávetőleg I. kompressziós fokozatú, valamint 1 db II. kompressziós SIGVARIS Traditional (természetes gumi alapanyagú) térdharisnyát. Az alsó harisnya innovatív kötésmódja következtében segíti a felső harisnya felvételét valamint levételét, illetve a seben használt kötszert is biztonságosan helyén tartja.

A beteg bőrével kizárólag pamut anyag érintkezik.

A tapasztalatok szerint az alsó harisnya használata éjszaka is szükséges, így ebből a harisnyából a készlet kettőt tartalmaz, egyet nappali, egyet éjszakai viseletre.

A II. kompressziós harisnya viselete kizárólag nappalra ajánlott.

Úgy az alsó, mint a felső harisnya méretezése megfelel a szokásos SIGVARIS mérettáblázatnak, azaz 12 standard méretben készül, anatómiailag követi a láb formáját.

A pólya megfelelő használatához hozzáértés, türelem és idő szükséges, míg az ULCER-X kitet a beteg egyedül, otthon is fel tudja venni.

A SIGVARIS ULCER-X KIT



Bővebb információért forduljon a SIGVARIS magyarországi hivatalos képviselőjéhez!

COMPRI-MED KFT.

1062 Budapest, Aradi u. 41.,

tel/fax: (1) 311-1883, mobil: (30) 949-3700.

## Soltész emlékérmesek

DR. BARTOS GÁBOR, DR. BIHARI IMRE,  
DR. JÁMBOR GYULA, DR. NEMES ATTILA, DR. MARKOVICS GABRIELLA

A Soltész Emlékérem (1. ábra) meg-  
alapításának és adományozásának gondolata  
már nem sokkal *Soltész Lajos* halála után  
felmerült, a Magyar Angiológiai Társaság  
akkori vezetőségében. Az erről szóló hatá-  
rozatot a MAT 1982. március 19-én tartott  
ülésén hozták meg. Az elhatározás szövege az  
akkori jegyzőkönyv alapján a következő volt:  
„A főtitkár javasolja a MOTESZ-től kapott  
információ alapján, a prof. dr. Soltész Lajos  
Emlékérem alapítását. A vezetőség egy-  
hangúan megszavazta e javaslatot és  
megbízta az Országos Érsebészeti Intézet,  
illetve a Szív és Érsebészeti Klinikáról résztvevő tagokat,  
hogy a szobrászati feladatok megoldására, illetőleg  
a feltételekkel kapcsolatos javaslatait a következőkben  
megtegye.” A szobrászkeresés feladatát *Nemes Attila*  
vállalta és találta meg *Borsos Miklós* személyében.  
Az Emlékérmet 1982-es alapítása után, 1985-ben adták át  
először. Eleinte évente, 1993-tól kezdve két évente adták  
át az Angiológiai Napok keretében. 2003-ban két, 1985-ben  
és 2019-ben három személy kapta meg a magyar érsebészet  
legnagyobb kitüntetését.



1. ábra. Soltész  
Emlékérem. Alapítva: 1982  
(Borsos Miklós munkája)

*Urai László* (1920-1987) (2. ábra),  
belgyógyász, angiológus, az orvostudo-  
mányok doktora, egyetemi tanár, 1946-ban  
nyert diplomát. Három budapesti klinikán  
dolgozott, utolsó munkahelye, 1966-tól,  
Budapesten a IV. sz. Belgyógyászati Klinika  
(később Országos Kardiológiai Intézet) volt.  
Számos belföldi és külföldi tanulmányúton  
vett részt. Ugyancsak számos neves tudomá-  
nyos társaság tagja és tisztségviselője volt,  
bel- és külföldön egyaránt. A Magyar  
Angiológiai Társaság főtitkára, majd elnöke  
lett. Úttörő érdemei vannak a magyar  
angiológia megteremtésében, művelésében, oktatásában,  
valamint képviselésében. *Bugár-Mészáros Károly* után ő lett  
a magyar angiológia vezető személyisége.

*Bugár-Mészáros Károly* (1900-1989) (3. ábra) bel-  
gyógyász, angiológus, az orvostudományok doktora,  
egyetemi magántanár. Eredetileg nem orvosnak készült,  
csak a körülmények alakulása miatt választotta ezt a hivatást.  
A budapesti egyetemen 1923-ban szerzett orvosdoktori  
diplomát. Belgyógyászati, tüdőgyógyászati és ideg-  
gyógyászati szakképesítése volt. Német, olasz, francia és



2. ábra. Urai László, 1985



3. ábra. Bugár-Mészáros  
Károly, 1985  
„honoris causa”



4. ábra. Stefanics János,  
1985  
„posthumus honoris causa”



5. ábra. Papp Sándor, 1986

angol nyelven beszélt, ezenkívül görögül és latinul is. Ez utóbbin jó társalgási szinten. Több budapesti intézményben dolgozott, 1950-től a Szent István Kórház egyik osztályvezető belgyógyász főorvosa lett. Angiológiával 1927 óta foglalkozott. Számos külföldi tanulmányutat tett neves európai intézetekben. „Az érbetegségek diagnosztikája kór- és gyógytana” című könyve 1944-ben jelent meg, amely a magyar angiológia bibliája. 1945-től egyetemi magántanár, 1952-től kandidátus, 1981-től az orvostudományok doktora volt.

Szent István kórházi osztálya a magyar angiológia első fellegvára lett. Több neves vezető angiológust nevelt. 1961-ben a MAT elődjének, a Magyar Sebész Társaság Angiológiai Sectiojának alapító elnöke volt. A Prágában, 1961-ben megalakult Nemzetközi Angiológiai Unió tagjává tette a magyar szervezetet. 1972-ben, a Magyar Angiológiai és Érsebészeti Társaság örökös elnökévé választották. Tiszteletére a MAÉT, 1995-ben, Bugár-Mészáros Károly Emlékéremet alapított.

*Stefanics János (1914-1982) (4. ábra)*, sebész, érsebész, kandidátus, sebészeti és érsebészeti iskolaalapító, a magyar érsebészet második, kiemelkedő úttörő tagja, egyetemi tanár. Budapesten nyert orvosi diplomát 1938-ban. Sebészeti szakképesítését a Bakay Klinikán szerezte. 1942-1945 között frontszolgálatot teljesített, ezután váltakozva dolgozott a budapesti II. sz. és a III. sz. klinikákon, ill. a Mosonmagyaróvári Kórházban, mindegyik helyen vezetőként. Előbb a gastroenterologia területén végzett jelentős munkát. Érsebészeti tevékenységét a Baross utcai klinikán kezdte. Idővel kialakította a második hazai érsebészeti centrumot, ahonnét több kiváló, vezető érsebész került ki. Több bel- és külföldi tudományos társaság tagja volt. *Mihael E, DeBakey-t* 1973-as látogatása során klinikáján látta vendégül. 1975-1979 között a Magyar Sebész Társaság elnöke.

*Papp Sándor (1923-2006) (5. ábra)*, érsebész, klinika igazgatóhelyettes, kandidátus, a magyar érsebészet alapító alakjainak egyike, egyetemi tanár. Előbb *Stefanics*, majd *Soltész* professzor munkatársa és segítője volt a magyar érsebészet kifejlesztésében. A nagyerek sebészetének első hazai úttörője, az első carotis desobliteratio és az első

aorto-bifemorális bypass elvégzője. Általános és szívsebészetet is művelt. Nagy elméleti tudású és kiváló manualitású szakember volt. 1992-ben Balassa emlékéremet kapott.

*Kiss Tibor (1922-2009) (6. ábra)*, sebész, érsebész, az orvostudományok doktora, a modern magyar érsebészet egyik megalapítója, egyetemi tanár. Diplomáját Budapesten 1946-ban szerezte meg. Előbb a budapesti, majd a pécsi Anatómiai Intézetben dolgozott, azt követően lett sebész. Nagytudású, kiváló manualitású operatőr volt. Előbb a Pécsi II. sz., majd az I. sz. Sebészeti Klinikán lett tanszékvezető egyetemi tanár. Később mindkét klinikát ő vezette. Hazánkban 1989-ben elsőként végzett laparoscopos cholecystectomiát. Tudományos munkásságát a sympaticus idegrendszer és a perifériás keringés területén fejtette ki. 1969-től megszervezte az érsebészetet, megalapítva „a pécsi iskolának” nevezett első hazai, vidéki érsebészeti centrumot. Számos neves sebész és érsebész vezetőt nevelt. A Balassa Emlékéremet 1984-ben nyerte el.

*Szabó Imre (1924-2016) (7. ábra)* pályáját Győrben, *Petz Aladár* mellett kezdte, majd a Városmajori Klinikára került, ahol *Soltész Lajos* professzor legközelebbi munkatársa, barátja és az első hazai érsebészeti osztály megteremtésében segítője lett. A magyar érsebészet „nagy öregje”, minden fiatal érsebész „Ricsi bácsija”. Végig élte és dolgozta a hazai érsebészet hőskorát. Részt vett ezen új sebészeti szakág sok küzdelemmel járó kifejlesztésében és a terhek vállalásában. Kitűnő manualitásával segítette az új módszerek kidolgozását, vállalta a fiatalok oktatását és első műtétek leasszisztálását. A korai idők érsebészei közül szinte kivétel nélkül mindenki tanítója, segítője volt. Szerény, barátságos természete miatt, nem volt ugyan előtérben, de nélküle sokkal szegényebb lenne érsebészetünk. Munkássága során összegyűjtötte osztályuk első időkben végzett érműtéteit. Pótolhatatlan kár, hogy mindez nem került közlésre és részben el is vészett. Élete végéig szoros kapcsolatot tartott a Városmajori Klinikával.

*Radó György (1918-1998) (8. ábra)*, bőrgyógyász, orvos ezredes, phlebologus, a vénás betegségek gyógyításának egyik hazai úttörője. Debrecenben nyert orvosi diplomát, Ezt követően a keleti frontra került munka-



6. ábra. Kiss Tibor, 1987



7. ábra. Szabó Imre, 1988



8. ábra. Radó György, 1989



9. ábra. Solti Ferenc, 1991

szolgálatosként. Később részt vett az antifasiszta ellenállásban, A háború után bőrgyógyász lett, majd katonaoorvos, 1953-tól a Honvéd Kórház parancsnoka, 1956-ban orvosi esküjének megfelelően mindkét oldali sebesülteket gyógyította, védte. 1957-ben letartóztatták, halálbüntetés fenyegette. Ettől csak volt betegei, a sebesült szovjet tisztek mentették meg, de 12 éves börtönbüntetésre ítélték, négy év múltán szabadult.

Bőrgyógyászként, majd gondozóintézeti főorvosként dolgozott. *Soltész Lajos* tanácsára a vénás betegségek gyógyításával kezdett foglalkozni. Kiváló specialista lett, a kompressziós kezelés egyik úttörője. Szakirodalmi munkássága is jelentős. A Magyar Angiológiai Társaságban is aktívan tevékenykedett, a phlebológiai szekció első vezetője volt. Halála után, egy ideig, a Honvédkórház az ő nevét viselte.

*Solti Ferenc (1921-2009) (9. ábra)*, belgyógyász, kardiológus, a Semmelweis Egyetem professzora. A BOTE-en kapott diplomát 1947-ben. A budapesti I. sz. Belgyógyászati Klinikán dolgozott, majd 1970-től a Városmajori Klinikán. A műtetre kerülő betegek előkészítésével a szívsebészetet támogatta. Specialitása a szív ritmuszavarainak gyógyszeres és paceamakeres gyógyítása volt. Kutató munkáját is nagyrészt e területen végezte. Részt vett a magyar pacemaker előállításában. Más területeken is kiterjedt, sikeres kutatásokat végzett. Kiváló egyetemi oktató volt, a postgraduális oktatásban is jelentős szerepet játszott, több kiváló tanítványt nevelt. Hatalmas tudományos munkásságot fejtett ki, mintegy 400 írott közleménye és kb. 300 tudományos előadása volt. Ismert volt a nemzetközi kardiológiai tudományos világban. Az MTA doktori fokozatot 1968-ban nyerte el, 1991-ben Semmelweiss díjat kapott.

*Jámbor Gyula (1939- ) (10. ábra)*, sebész, érsebész, kandidátus, egyetemi docens. 1964-ben nyert orvosi diplomát Budapesten. *Stefanics* professzor mellett dolgozva lett sebész és érsebész szakorvos. Főnöke egyik közeli munkatársa volt, s az érsebészeti munkacsoport vezetője. Az autolog femoro-cruralis és femoro-distalis vena saphena bypass első számú magyarországi tudományos megalapozója és úttörője. Több mint 1200 ilyen műtétet végzett. Ő végezte az első hazai artéria mesenterica superior



10. ábra. Jámbor Gyula, 1993



11. ábra. Csengődy József, 1995

desobliteratit 1972-ben. 1996-ban megszervezte az I. sz. Sebészeti Klinikán az addig ott nem művelt érsebészetet. 2004-ben a Flór Ferenc Kórház vezető érsebésze lett. Az 1980-as években két periodusban volt a MAÉT főtitkára.

*Csengődy József (1928-2012) (11. ábra)*, sebész, anaesthesiologus, érsebész szakorvos, címzetes egyetemi docens. Budapesten, 1954-ben nyert orvosi diplomát. Tapasztalt sebész, érsebész, anaesthesiologus és invenciózus újító, jártasságot szerzett az endoscopyban is. *Stefanics János* professzor közeli munkatársa lett, kiváló oktató. Ő végzett elsőként érsebészeti Doppler vizsgálatokat Magyarországon. Számos, neves nyugat-európai intézetben járt tanulmányúton. 1968-ban, egy évig, Észak-Jemenben, Sanaá-ban vezető sebész főorvos volt. 1980-ban a Weil Emil, ma Uzsoki Utcai Kórház osztályvezető sebész főorvosa lett, ahol több új sebészti eljárást, többek között az LC-t is bevezette. Jelentős, többoldalú tudományos tevékenységet végzett, 121 cikk és 86 előadás szerzője. Az MST-nek és a MAÉT-nek is vezetőségi tagja volt. Tagja volt továbbá a Sebész és az Érsebész Kollégiumnak, Számos, jelentős állami elismerést és kitüntetést kapott.

*Nemes Attila (1938- ) (12. ábra)* 1963-ban vette át diplomáját, Budapesten. A Városmajori Klinikán kezdte működését, ahol a szakmai grádus minden fokát végigjárva *Kudász, Soltész és Szabó* professzorok után egyetemi tanár és intézetigazgató lett. Az egyetem rektorhelyettese volt. Kutatóként az érptlás problémáival, köztük a Solcoseryl



12. ábra. Nemes Attila, 1997



13. ábra. Tasnádi Géza, 1999



14. ábra. Gunther Tamás, 2001



15. ábra. Dzsinih Csaba, 2003



16. ábra. Tarsoly László,  
2003 „honoris causa”



17. ábra. Acsády György,  
2005

graft tökéletesítésével és érragasztással is foglalkozott. Kitűnő rajzkészséggel számos érsebészeti könyv illusztrátora. Fő területe az érsebészeti szövödmények és a malpractice vizsgálata, valamint az oktatás volt. Doktori értekezése az előbbiről, míg *Acsády György*vel közösen írt érsebészeti tankönyve az utóbbi témáról szól. Balassa emlékéremmel is kitüntették.

*Tasnádi Géza* (1937-2019) (13. ábra) a Hatvani Kórházból került a budapesti Heim Pál Kórházba, ahol a gyermeksebészet művelése mellett az érmalformációk tanulmányozására és gyógyítására specializálódott. *Soltész Lajos* közvetlen tanítványa, munkásságának egyik folytatója. Tudományos értekezései is e témával foglalkoznak, számos hazai és nemzetközi szakkönyv társszerzője. A hazai szakkörökben vezető személyiség, nemzetközi elismertsége is jelentős. Rendszeresen hívták külföldre egy-egy speciális műtét elvégzésére. Részt vett az érmalformációk u. n. hamburgi osztályozásának kidolgozásában. 2018-ban Pro Universitate díjat kapott.

*Gunther Tamás* (1937-2009) (14. ábra), sebész, érsebész. A Győri Kórházban 1961-től dolgozott. A helyi érsebészeti osztályt megalapító *Mátrai Tamás* első munkatársa lett. A későbbiekben ő vitte ezt a területet. Az akkori érsebészet teljes palettáján végeztek műtéteket. Végül önálló érsebészeti osztály vezetője lett. Tiszteletére, halála után a Kórház emléktáblát állított.



18. ábra. Dlustus Béla,  
2009



19. ábra. Kollár Lajos,  
2009



20. ábra. Mogán István,  
2011



21. ábra. Mátyás Lajos,  
2013

*Dzsinich Csaba* (1942-) (15. ábra), 1969-ben kezdte érsebészeti pályafutását a Városmajori Klinikán. Több külföldi tanulmányúton vett részt. Németországban szerzett érsebészeti szakképesítést, így ő lett az első magyar érsebész szakorvos. Egy ideig ő vezette a klinikai érsebészetet és oktatta a szakorvosjelölteket. A veseartériák sebészetéből írta kandidátusi disszertációját. Az érsebészet minden ágát magas színvonalon műveli. Különösen az aorta aneurysmák sebészetében, a stent graftok beültetésében és a hibrid műtétek végzésében tűnt ki. Professzori rangot nyert. Jelentős szerepet játszott a hazai és nemzetközi tudományos társaságokban. Nemzetközileg a legelismertebb Magyarországon dolgozó érsebész. Később a Magyar Honvédség Egészségügyi Központjában lett osztályvezető. Balassa emlékéremmel is kitüntették.

*Tarsoly László* (1939-2014) (16. ábra), sebész, érsebész. Diplomája megszerzése után a Zalaegerszegi Kórház Sebészeti Osztályára került. A hetvenes években elkezdett érsebészeti tevékenység vezetője lett. Jó kapcsolatokat tartott a Városmajori Klinikával. Aktívan vett részt a MAÉT munkájában.

*Acsády György* (1947-) (17. ábra), orvosi diplomáját 1971-ben nyerte el. Egész pályafutása a Városmajori Klinikához kötődik, amelynek több évtizedes munka után tanszékvezető egyetemi tanára és hatodik igazgatója, valamint az egyetem dékánja lett. A phlebológia egyik országos szaktekintélye, aki számos területen végzett úttörő tevékenységet és jelentős irodalmi munkásságot fejtett ki. Első szerzője a legújabb magyar érsebészeti tankönyvnek és atlasznak. A bel- és külföldi tudományos társaságokban aktívan tevékenykedett. A MAÉT elnöke volt.

*Dlustus Béla* (1940-2016) (18. ábra), katonarvos, érsebész, 1965-ben nyerte el orvosi diplomáját a Semmelweis Egyetemen, ezután 16 évig a fővárosi Balassa Kórházban dolgozott. 1969-ben sebészeti szakvizsgát tett, 1983-tól a Honvéd Kórház Sebészeti Osztályán dolgozott. Neve fémjelzi az ottani Érsebészeti Osztály megalapítását és vezetését. Magas színvonalú érsebészeti tevékenységükkel az Osztály országosan ismert lett. Számos kitűnő szakembert nevelt. Egyik alapítója volt az 1998-tól hét alkalommal, Balatonkenesén megrendezett Fiala Angiológusok Fórumának.

*Kollár Lajos (1948- ) (19. ábra)*, a Pécsi egyetemen szerzett diplomát, 1976-ban. Érsebészeti tevékenységét a Pécsi II. sz. Sebészeti Klinikán kezdte *Kiss Tibor* professzor mellett az u.n. „pécsi triumviratus” tagjaként. A magyar haemorheologia kiemelkedő képviselője lett. Több érsebészeti területen, pl. az angioscopos műtétekben, a cryo-varicectomiában, az első hazai carotis stent beültetésében, ill. a hasi aorta aneurysmák stent-graft kezelése terén, úttörő munkát végzett. Később a Pécsi Sebészeti Tanszék igazgató egyetemi tanára lett. Kitűnő munkatársak nőttek fel mellette. Publikációs tevékenysége is jelentős Több állami elismerésben és kitüntetésben is részesült.

*Mogán István (1946- ) (20. ábra)*, orvosi diplomáját 1970-ben nyerte el. Ezt követően a Városmajori Klinikán dolgozott 1993-ig. A Budai MÁV Kórház osztályvezető főorvosa volt 1995 és 2002 között. Számos külföldi tanulmányúton járt neves intézetekben. Meghonosította a carotis eversios endarterektomiát, a cruralis és a pedalis bypass műtéteket, továbbá az aorta aneurysmák műtéti kezelését. 2002-ben a Budapesti Szent Imre Kórház újonnan létesített Érsebészeti Részlegének vezető főorvosa lett. Klinikai munkája mellett publikációs munkása is jelentős. Aktívan részt vett a MAÉT munkájában, amelynek 2011-ben elnöke lett.

*Mátyás Lajos (1948- ) (21. ábra)*, Debrecenben avatták orvosdoktorrá, 1973-ban. Az újonnan alapított miskolci érsebészeti osztályra 1981-ben került, amelynek második osztályvezető főorvosa lett, és amelyet regionalis központtá fejlesztett. Az országban elsőként alkalmazták az endoscopos eljárásokat, mind a diagnosztikában, mind a műtéteknél. Ő végezte az első, dokumentált in situ vénás bypass műtétet. Nagy érdeme, hogy Magyarországon elsőként végzett stent-graft beültetést hasi aorta aneurysmánál, 1998-ban. A hibrid műtétek egyik úttörője. Aktívan részt vett az Intézmény fejlesztésében és közéleti tisztségeket viselt pl. a helyi rádióban és sportban. A MAÉT vezetőségi tagja, két periódusban főtájkára, egy időszakban elnöke volt.

*Entz László (1951- ) (22. ábra)*, a SOTE-n szerzett diplomát, 1976-ban, ugyanabban az évben a Városmajori Klinika munkatársa lett. Sebész, érsebész, radiologus szakorvos, egyetemi tanár. Ő vezette be 1991-ben

Magyarországon a carotis eversios endarterektomiát. 1995-ben kandidátusi fokozatot szerzett, majd 2006-ban habilitált. 2012-2016 között az Érsebészeti Tanszék és a klinika érsebészeti profiljának vezetője volt. A Magyar Angiológiai és Érsebészeti Társaság vezetőség tagja, 2005-2011 között főtájkára.

*Menyhei Gábor (1955- ) (23. ábra)*, diplomáját a Pécsi Orvostudományi Egyetemen

1981-ben kapta meg. Orvosi munkásságát a Pécsi I. sz. Sebészeti Klinikán 1982-ben kezdte el. Érsebészeti szakvizsgáját 1988-ban tette le. Az ütőeres érsebészet mellett a phlebológiát is magas színvonalon műveli. Elismertek voltak tüdőembolia profilaxis céljából készített gépi érvarratos v. cava inferior-plicatios műtétei. Angliában is dolgozott. 2008-ban habilitált, 2010-től a PTE KK Érsebészeti Klinikai Tanszékének tanszékvezető egyetemi tanára. 1999 óta a MAÉT vezetőségi tagja, 2013 és 2015 között a Társaság elnöke volt.

*Kozlovsky Bertalan (1951- ) (24. ábra)*, Debrecenben lett orvosdoktor 1975-ben. Az ottani Sebészeti Klinikán dolgozott. A sebészeti szakképesítés után érsebészeti szakvizsgát is tett. *Gyurkó György* munkatársaként részt vett a debreceni érsebészet kifejlesztésében. Foglalkozott az aorta dissecaló aneurysmáinak megoldásával. 1995-ben a nyíregyházi, érsebészeti profilú Sebészeti Osztály vezetője lett a nagy elődök, *Eisert Árpád* és *Dohanics Sándor* után. Eredményes munkájuk jutalmául elnyerték a 2007. évi, jól sikerült, Angiológiai Napok rendezési jogát. A nyugdíjkorhatár elérése után ma is aktívan részt vesz az Érsebészeti Részleg munkájában.

*Bartos Gábor (1931- ) (25. ábra)*, a Pécsi Orvostudományi Egyetemen nyert diplomát 1955-ben. Ebben az évben lépett be a Pécsi Műtéti Intézet kötelékébe *Karlinger Tihamér* és *Török Béla* professzorok munkatársaként. Munkacsoportja kidolgozta a magyar érprotézist,



**22. ábra.** Entz László, 2015



**23. ábra.** Menyhei Gábor, 2017



**24. ábra.** Kozlovsky Bertalan, 2019



**25. ábra.** Bartos Gábor, 2019 „honoris causa”



**26. ábra.** Hetényi András, 2019 „honoris causa”

amely szabadalmi oltalmat nyert, a RICO Kötőszerművek gyártotta és klinikai alkalmazásban volt a kilencvenes évek elejéig. 1967-től a II. sz. Sebészeti Klinikán, *Karlinger Tihamér* és *Kiss Tibor* professzorok mellett dolgozott, ahol elkezdte az érsebészet művelését. A bangladesi polgárháború idején, 1971-ben, tábori sebészeti kórházi részleget vezetett. 1973 és 1997 között a Dunaújvárosi Kórház Általános Sebészeti Osztályát vezette. Ott is létrehozták az érsebészetet. 2003-tól munkatársaival, több tucat közleményben, megírták a magyarországi artériás érsebészet történetét.

*Hetényi András (26. ábra).* A veszprémi kórházban elsőként kezdte el az érsebészetet a múlt század hetvenes-nyolcvanas évek fordulóján. 1980-ban lett szakorvos, 1985-ben Ajkán is megteremtette az érsebészetet, s megszervezte az ország első önálló érsebészeti osztályát.

1997-ben Székesfehérvárra került, ahol a Sebészeti Osztály Érsebészeti Részlegének vezetője lett 2001-ben. Ő vezette itt be a supraaorticus erek helyreállító műtéteit. Működése idején számos mélyvénás rekonstrukciót is végeztek. Magas színvonalon művelte az ütőerek sebészetét, de igazi érdeklődési területe a phlebológia és a Doppler vizsgálatok voltak. Számos új eljárást dolgozott ki, s alkalmazott először Magyarországon, mint pl. a szivaccsal kombinált kompressziós pólyát, a feltárt mélyvéna védelmét PTFE spirállal, a sapheno-femorális reflux megszüntetésére külső szűkítést, stb. Tanítványai több hazai és külföldi érsebészeti osztályon vitték tovább a tőle tanultakat. Társszerzője a kilencvenes években megjelent Doppler monográfiának. Sok éven keresztül elzárkózott a szakmai kapcsolatoktól. Ez évben távozott közülünk.

## FOR HEALTHY LEG!



**Pharmatextil**

PRODUCTION OF MEDICAL  
COMPRESSION TEXTILES

**Pharmatextil** manufactures medical and preventive compression stockings for leg and arm, stump socks and joint supports.

- Prophylactic stockings with compression category I. are suitable for health protection and the prevention of thrombosis and embolism. (**ELASTOFIT**, **ELASTOBOL** stockings for leg).
- Among our medical stockings with compression category II., III., IV. you can find the entire range of arm and leg stockings and stump socks as well (**ELASTOMED KOMFORT**, **ELASTOMED STRETCH**, **ELASTOSTAR**, **ELASTOBAR**, **ELASTOLIM** products).
- Flexible joint supports is for patients suffering from joint problems. **ELASTOSTAR** product line includes ankle, knee, wrist and elbow supports.

You can find more detailed information of our products on our website: [www.pharmatextil.hu](http://www.pharmatextil.hu)





Lithium  
akkumulátor,  
6 órás  
működés

Vízhatlan,  
teljes egészében  
fertőtleníthető



Használható  
kórteremben,  
műtőben,  
sürgősségi  
ellátásban

Color  
doppler  
vizsgálat

Wi-Fi  
csatlakozás



Izinta Kereskedelmi Kft.  
1121 Budapest, Konkoly Thege M. út 29-33.  
Telefon: +36 1 392 2654 • www.izinta.hu

Kapcsolattartó:  
Merse Anita  
merse.anita@izinta.hu  
+36 20 953 6154  
www.izinta.hu

## Eltávozott Dr. Tóth Gyula érsebész főorvos

A megdöbbentő és fájdalmas hírt 2019. június 25.-én reggel kaptuk.

Egyetemi tanulmányait a Debreceni Orvostudományi Egyetemen végezte. A diploma megszerzése után érdeklődése hamar az érsebészet felé fordult. Kiképzését a Honvédkórház Érsebészeti Osztályán Dr. Dlustus Béla főorvos úr vezetésével kapta, majd szakvizsgáját a Városmajori Érsebészeti Klinikán tette le. Ezt követően, 25 éven át a Honvédkórház érsebészeti csapatának értékes tagjaként tevékenykedett. Új munkahelye mellett is mindvégig rendszeres szakmai és baráti kapcsolatban maradtunk. Az Országos Baleseti és Sürgősségi Intézet Érsebészeti Részlegének vezetőjeként, 2011-től értékesen járult hozzá a főváros lakosságának ellátásához, különös tekintettel a baleseti sebészeti komplex műtétekre.

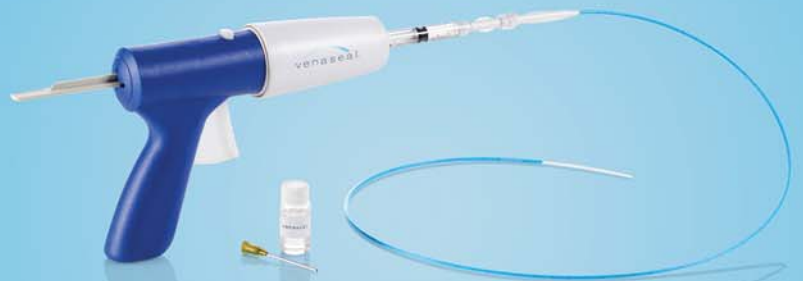Értékes tevékenységére, hirtelen elvesztése döbbenett rá mindenkit. Kimeríthetetlen szakmai hivatástudata, szinte korlátlan terhelhetősége, mindannyiunk számára példamutató volt. 64 évet élt, nyugdíjba készült. Rendkívüli szakmai erényei mellett, az emberekre odafigyelő, barátságos, érzékeny egyéniség volt, akinek emlékét szeretettel megőrizzük.



*Prof. Dr. Dzsiniich Csaba,  
Dr. Vallus Gábor,  
Dr. Bihari Imre*



# BUILDING LONG-TERM EVIDENCE WITH HIGH CLINICAL STANDARDS



VenaSeal™  
Closure System

## VeClose Extension Study<sup>1</sup> 5-year results

- **PURPOSE:** 5-year follow-up study to assess the long-term safety and efficacy of the VenaSeal™ closure system.
- VenaSeal™ closure system closure rates remained strong at 5-year follow-up.
- No DVT, PE, or adhesive-related allergies were reported in the VenaSeal™ closure system cohort.

## VeClose Extension Study 5-year Snapshot

	VenaSeal™ closure system
5-year closure rates (> 5 cm segment) <sup>2</sup>	94.6%* (53/56 <sup>†</sup> )
Venous Clinical Severity Score (VCSS) improvement from baseline	75%** (n = 47)

When asked at 5 years,  
**9 out of 10**  
VenaSeal™ closure system  
treated patients would choose  
the VenaSeal™ procedure again.

### VeClose Extension Study comparator:

ClosureFast™ procedure 5-year closure rate: 100%\* (33/33)  
Proebstle ClosureFast 5-year: 91.9%<sup>3</sup> (225/295)

## DISCOVER THE VENASEAL™ CLOSURE SYSTEM DIFFERENCE

\*VenaSeal™ closure system and ClosureFast™ procedure closure rates not statistically different ( $p = 0.2638$ ).

<sup>†</sup>VenaSeal™ closure system includes 9 roll-in patients.

\*\*VenaSeal™ closure system roll-in patients were not included in this analysis (n = 9).

## HABSZKLEROTERÁPIÁS TANFOLYAM

### Ultrahang-vezérelt injekciós habszkleroterápia

Tisztelt Doktornő, Doktor Úr!

Az APC Pharmlog Hungary Kft akkreditált, pontszerző habszkleroterápiás tanfolyamot hirdet. A tanfolyam célja a résztvevőkkel megismertetni a vénás rendszer ultrahang-szerkezetét és ultrahang vizsgálatát, a terápia indikációit és kontraindikációit, a szklerotizáló anyagokat és a szklerotizáló habot, a sztenderdizált hab elkészítését, az esetleges komplikációkat és mellékhatásokat, a szkleroterápia kombinációját lézerkezelésekkel, és a korlátokat. A tanfolyam elméleti és egyben gyakorlati jellegű, tehát egy (vagy több) páciensen bemutatásra kerülnek az ultrahang használatának technikai és a habszkleroterápiás technikák alkalmazásai. Célunk továbbá bemutatni, hogyan teheti Ön is praxisa részévé az injekciós visszérkezeléseket.

**A tanfolyam időpontja: 2019.10.26 (szombat)**

**Helyszíne: Theta Pest Rendelő (1091 Budapest, Vaskapu utca 17)**

**Részvételi díj: 30.000 forint**

OFTEX-kód: **SE-TK/2019.II/00051**

Cím: A vénás betegségek kezelése a legkorszerűbb szkleroterápiás módszerekkel (habszkleroterápia, radiofrekvenciás, lézer, MOCA stb. kezelés)-lehetőségek és korlátok

Szervező: **APC Pharmlog Hungary Kft**

Pontszám: 16

**Az előadók:**



Dr. Szabó Attila  
érsebész főorvos



Dr. Rozsos István  
érsebész főorvos



Dr. Dósa Edit  
Intervenciós  
radiológus



APC Pharmlog Hungary Kft  
1164 Budapest, Szabadföld út 79  
Asz: 26339739-2-42 cgisz: 01-09-324990

További információval kapcsolatban vagy a tanfolyamra való jelentkezési szándéka esetén, kérem vegye fel a kapcsolatot az alábbi kontaktok valamelyikével:

Labancz Attila

[attila.labancz@apcpharmlog.eu](mailto:attila.labancz@apcpharmlog.eu)

+36 (30) 960 4985

Szmolár Mária

[maria.szmolar@apcpharmlog.eu](mailto:maria.szmolar@apcpharmlog.eu)

+36 (20) 949 4150

#### ÉRBETEGSÉGEK • THE HUNGARIAN JOURNAL OF VASCULAR DISEASES

A Magyar Angiológiai és Érsebészeti Társaság, valamint a Magyar Cardiovascularis és Intervenciós Radiológiai Társaság tudományos folyóirata  
*Scientific Journal of the Hungarian Society for Angiology and Vascular Surgery and of the Cardiovascular and Interventional Radiological Society of Hungary*

FŐSZERKESZTŐ: DR. BIHARI IMRE • ISSN 1218-36-36

**Szerkesztőbizottság:** dr. Acsády György, dr. Dzsinih Csaba, dr. Hüttl Kálmán †,  
dr. Jámbor Gyula, dr. Lázár István, dr. Mátyás Lajos, dr. Nagy Endre, dr. Entz László

**Rovatvezetők:** Artériák: dr. Nemes Attila • Vénák: dr. Menyhei Gábor • Endovascularis beavatkozások: dr. Kollár Lajos  
Alaptudományok: dr. Monos Emil † • Haemorheológia: dr. Pécsváradi Zsolt • Belgyógyászat: dr. Meskó Éva  
Radiológia: dr. Battyáni István • Gyermekkori érbetegségek: dr. Tasnádi Géza †

Kiadja az Ádám és Bihari Kft. Felelős kiadó: az Ádám és Bihari Kft. ügyvezető igazgatója.

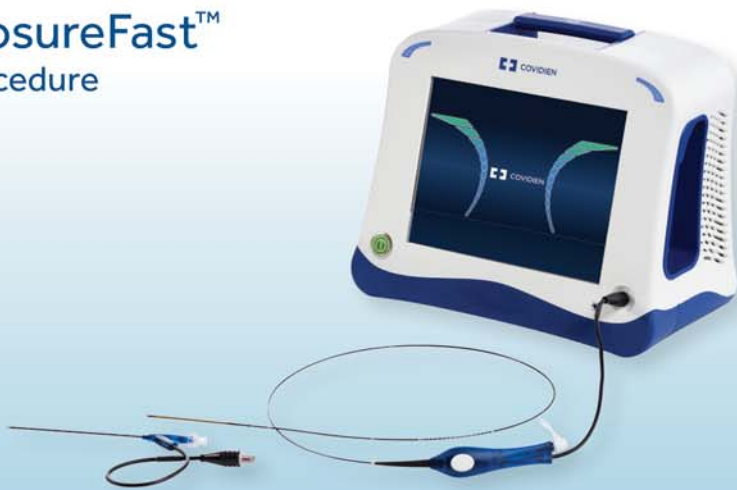Szerkesztőség címe: 1081 Budapest, Népszínház u. 42-44. Tel./Fax: +36-1- 3345-468.

Tervezőszerkesztő: Kincses Gábor • Nyomdai munkák: Szó-Kép Nyomdaipari Kft.

Honlap: <http://www.erbetegsegek.com/>

# TWO EFFECTIVE VENOUS REFLUX TREATMENT OPTIONS WITH CLINICALLY DEMONSTRATED OUTCOMES.<sup>1,2</sup>

## ClosureFast™ Procedure

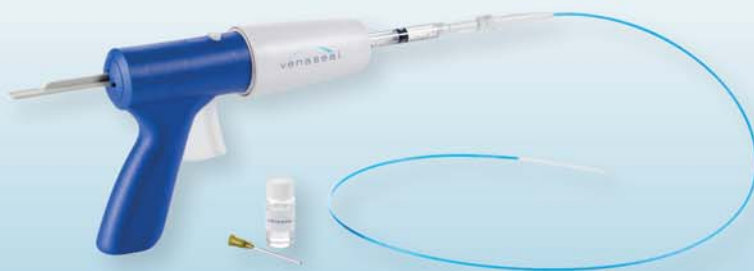

## ClosureFast™ Catheter

Segmental  
Radiofrequency  
Ablation

Five years of excellent clinical results<sup>2</sup> across thousands of patients.

## VenaSeal™ Closure System



## VenaSeal™ Closure System

Non-tumescent,  
Non-thermal,  
Non-sclerosant

A specially formulated medical adhesive that delivers improved patient comfort.<sup>1</sup>

1. Gibson K. A Randomized, Controlled Study Comparing Cyanoacrylate Adhesive Embolization With Radiofrequency Ablation For Treatment Of Incompetent Great Saphenous Veins VeClose Study, German Society of Phlebology, 2014.
2. Almeida JI, Kaufman J, Goekeritz O, et al. Radiofrequency Endovenous ClosureFAST versus Laser Ablation for the Treatment of Great Saphenous Reflux: A Multicenter, Single-Blinded, Randomized Study (Recovery Study). JVIR June 2009

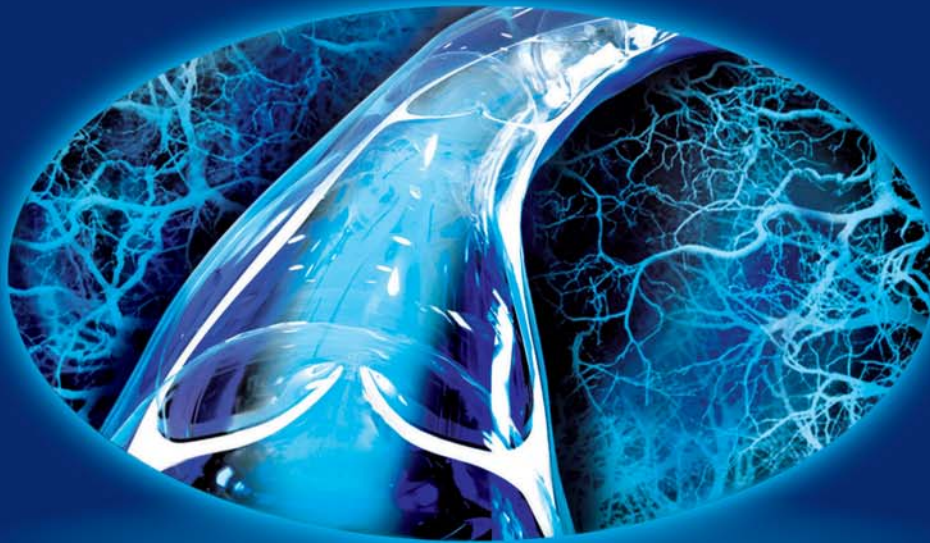
© 2015 Medtronic. All rights reserved. Medtronic, Medtronic logo and Further, Together are trademarks of Medtronic. All other brands are trademarks of a Medtronic company. – EU-15-352057 – 08/2015

**Medtronic**  
Further, Together

**detralex**<sup>®</sup>  
MIKRONIZÁLT tisztított flavonoid frakció

# Nemzetközileg elismert, nagyfokú hatékonyság<sup>1-8</sup>

krónikus vénás elégtelenségben és aranyérbetegségben



MPFF – Flavonoid komplex  
az átfogó vénavédelemért  
és komplett hatásért<sup>1-8</sup>



1 – Nicolaides AN, et al. *Int Angiol.* 2018; 37 (3): 181-254. 2 – Agarwal N, Kumkum Singh K, et al. *Ind J Surg.* 2017.01.09. DOI 10.1007/s12262-016-1578-7. 3 – Cospite M. *Angiology.* 1994;45(6):566-573. 4 – Lyseng-Williamson KA, Perry CM. *Drugs.* 2003;63(1):71-103. 5 – Perera N, et al. *Cochrane Database Syst. Rev.* 2012, 8:CD004322. 6 – Misra MC, Imlitemsu. *Drugs.* 2005;65(11):1481-1491. 7 – Pascarella L. *Curr Pharmaceutical Design.* 2007;13:431-444. 8 – Kakkos S, Nicolaides AN. *Int Angiol.* Epub Doi: 10.23736/S0392-9590.18.03975-5. 9 – QuintilesIMS database, Analytics Link, C5C worldwide, Euros, MAT Q2 2017 Analytics Link



A hatályos Alkalmazási előírás teljes szövegét megtalálja az Országos Gyógyszerészeti és  
Ételmezés-egészségügyi Intézet honlapján ([www.ogyei.gov.hu/gyogyszeradatbazis/](http://www.ogyei.gov.hu/gyogyszeradatbazis/)).

Magyarország átfogó egészségvédelmi szűrőprogramjának Főtámogatója  
Servier Hungária Kft. | 1062 Budapest, Váci út 1-3. | Telefon: 1-238-7799 | Fax: 1-238-7966 | [www.servier.hu](http://www.servier.hu)

Magyarország átfogó egészségvédelmi szűrőprogramja  
2018 - 2020

